

Laparoscopic treatment of a perorally extruding ventriculoperitoneal shunt

Laparoskopické ošetření perorálně extrudujícího ventrikuloperitoneálního shuntu

Dear Editor,

Hydrocephalus is a clinical condition that is characterized by an increase in intracranial pressure [1]. Hydrocephalus is commonly treated by ventriculoperitoneal shunt surgery, which allows the drainage of cerebrospinal fluid (CSF) from the ventricles into the peritoneum. The most common complications of this surgery are shunt dysfunction and infection. Although rare, complications may develop due to the abdominal end of the shunt penetrating the intra-abdominal organs [2].

Abdominal complications have been reported in the range of 24–47%, and gastrointestinal perforations are seen with a frequency of 0.1–0.7% [3]. Gastric perforations are very rare and have been reported as individual cases. Furthermore, all the reported cases in the literature have occurred in the pediatric age group [4].

Herein, we present the case of an adult patient who developed a gastric perfora-

tion 2 years after ventriculoperitoneal shunt surgery, which was treated laparoscopically. Because no such case has been reported in the literature, we aimed to discuss the diagnosis and treatment algorithm of adults with shunt-associated gastric perforation.

A 35-year-old female had a ventriculoperitoneal shunt for hydrocephalus that had developed following a spontaneous non-aneurysmal subarachnoid hemorrhage. The patient did not have any shunt-related symptoms for 2 years. Recently, the patient complained of increased vomiting following a history of a cold that developed 4 months before admission. The patient also complained of fever and night sweats. The patient was referred to our hospital after the distal part of the shunt catheter was seen extruding from the mouth after an episode of vomiting (Fig. 1).

Physical examination was normal. The catheter tip from the abdomen was actively working. Radiographs revealed that the catheter had perforated the stomach and

The Editorial Board declares that the manuscript met the ICMJE “uniform requirements” for biomedical papers.

Redakční rada potvrzuje, že rukopis práce splnil ICMJE kritéria pro publikace zasílané do biomedicínských časopisů.

B. Yoldas, A. Arpa, P. Aydin Ozturk

Department of Neurosurgery, Dicle University Medical Faculty, Diyarbakir, Turkey



Pinar Aydin Ozturk, MD

Department of Neurosurgery
Dicle University Medical Faculty
Diyarbakir
Turkey

e-mail: aydinpinar12@gmail.com

Accepted for review: 23. 4. 2024

Accepted for print: 31. 10. 2024

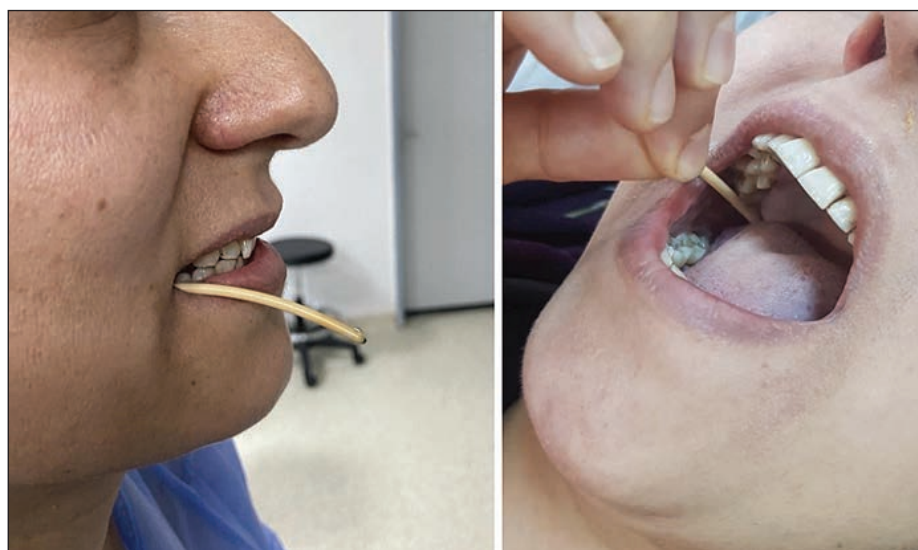

Fig. 1. The distal end of the catheter is seen exiting the mouth.

Obr. 1. Je vidět distální konec katetru vycházející z úst.

exited through the mouth. Although the ventricles were enlarged, CSF continued to flow through the catheter (Fig. 2).

Because CSF and blood analyses did not demonstrate any evidence of infection, the patient underwent laparoscopic surgery. Intraoperative evaluation revealed that the abdominal catheter had perforated the stomach, and significant granulation tissue was visible around the point of perforation. The catheter was laparoscopically excised at the site of perforation, and the stomach perforation was closed. The catheter was extended subcutaneously in the abdomen with a straight connector and fixed behind the liver. The patient was administered ceftriaxone and vancomycin for 14 days in the postoperative period. The patient was discharged without any complications.

Ventriculoperitoneal shunt surgery is performed for the treatment of hydrocephalus [2]. The most common complications

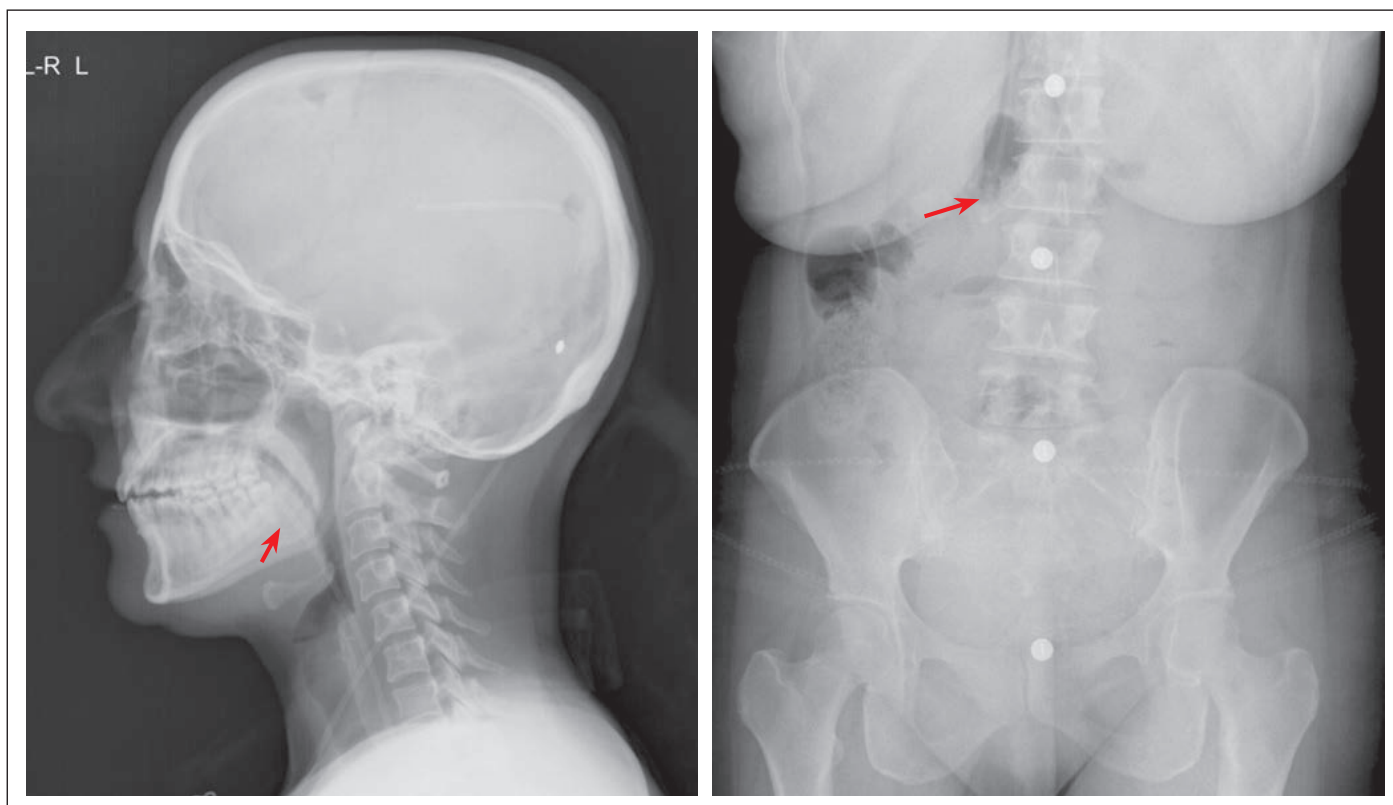


Fig. 2. The exit of the catheter is shown radiologically (arrows).

Obr. 2. Výstup katetru je zobrazen na rentgenu (šipky).

of ventriculoperitoneal shunt surgery are shunt malfunction and shunt infections [3]. The other complications include ventriculitis, meningitis, allergic reactions along the shunt course, pseudocyst formation in the abdomen, perforation of various places by the abdominal tip of the shunt, and entry of the shunt into the digestive system.

Hollow organ perforation by ventriculoperitoneal shunts is extremely rare (0.01–0.07%) [2]. Although perforation can occur in any part of the digestive system, it is commonly seen in the colon [4]. Gastrointestinal perforation can cause fatal complications such as peritonitis, intraperitoneal abscesses, fecal fistulas, meningitis, or sepsis [5].

The etiology of gastrointestinal perforations due to ventriculoperitoneal shunts remains unknown. Conditions such as myelomeningocele and congenital hydrocephalus predispose a patient for hollow organ perforation [2]. To date, 14 pediatric cases of gastric perforation due to ventriculoperitoneal shunt surgery have been reported. These gastric perforations were related to young age, male sex, malnutrition, silicone allergy, catheter length, previous abdominal surgery, and infection [8].

Peroral extrusion was reported in an 11-year-old girl with a known history of spina bifida who had undergone abdominal surgery. It had been known for 4.5 years that the peritoneal catheter was disconnected in her. In this patient, catheter removal and laparoscopic gastric repair were performed and a ventriculoperitoneal shunt was not re-inserted. Therefore, there was no risk of adhesion in the abdomen causing shunt dysfunction [5].

The case of a 72-year-old male, whose ventriculoperitoneal shunt catheter was incidentally detected in the stomach during percutaneous enterogastrostomy, has been reported in the literature. This perforation may have been related to the catheter being surrounded by a fibrous band. Although the patient had a gastric perforation, peroral extrusion was not observed [6]. Stomach perforation secondary to a shunt infection was observed in an 87-year-old male following ventriculoperitoneal shunt surgery. Peroral extrusion was not observed in this patient either, and the perforation was treated laparoscopically [7].

Peroral extrusion is a pathology that requires careful treatment. Management principles include catheter removal, repair of the

perforated area, and treatment of the infection, if any [8]. Catheter withdrawal techniques include gentle withdrawal of the catheter, laparotomy, and laparoscopic surgery. It is not always easy to remove the catheter due to adhesions to the affected organs [5]. It is known that revision surgeries may cause the development of adhesions and fibrosis in the abdomen and this may cause shunt dysfunction [9]. Since the risk of fibrosis and adhesion would be higher if the catheter was removed through laparotomy for gastric repair, we concluded that it would be more appropriate for our patient to remove the catheter and perform gastric repair via laparoscopic intervention. However, due to the risk of the omentum obstructing the shunt [10], the shunt was fixed behind the liver where there was less omentum.

A review of the literature revealed that no case similar to ours has been reported. Our patient was an adult female without a history of abdominal surgery who presented with a peroral shunt extrusion 2 years after the primary surgery. Our aim of reporting this case was to highlight the planning of the management of such patients.

Hollow organ perforation, although rare, should be considered in patients with shunt

dysfunction or signs of meningitis with a shunt in-situ. In patients presenting with peroral extrusion, the presence of infection should be investigated, and the treatment should be planned accordingly. In the absence of infection, laparoscopic surgery is a good treatment alternative to prevent secondary adhesions. Additionally, shunt transfer to behind the liver may be possible in the same session without widening the incision or making a new incision.

Conflict of interest

The authors declare they have no potential conflicts of interest concerning drugs, products, or services used in the study.

References

1. Aktiz Bicak E, Arpa A. Laryngeal mask anesthesia during surgical treatment of pediatric patients with hydrocephalus. *J Clin Trials Exp Investig* 2023; 2(3): 153–158. doi: 10.1007/BF03012981.
2. Sathyanarayana S, Wylen EL, Baskaya MK et al. Spontaneous bowel perforation after ventriculoperitoneal shunt surgery: case report and a review of 45 cases. *Surg Neurol* 2000; 54(5): 388–396. doi: 10.1016/s0090-3019(00)00334-7.
3. Coley BD, Kosnik EJ. Abdominal complications of ventriculoperitoneal shunts in children. *Semin Ultrasound CT MR* 2006; 27: 152–160. doi: 10.1053/j.sult.2006.01.009.
4. Sridhar K, Karmarkar V. Peroral extrusion of ventriculoperitoneal shunt: case report and review of literature. *Neurol India* 2009; 57(3): 334–336. doi: 10.4103/0028-3886.53283.
5. Akgün B, Aktaş EG, Erol FS et al. Ventriculoperitoneal shunt complications: evaluation of 75 cases. *FÜ Sağ Bil Derg* 2008; 22(2): 69–72.
6. Cohen-Addad DI, Hewitt K, Bell D. A ventriculoperitoneal shunt incidentally found in the stomach. *Radiol Case Rep* 2018; 13(6): 1159–1162. doi: 10.1016/j.radcr.2018.08.004.
7. Cheng JY, Lo WC, Liang HH et al. Migration of ventriculoperitoneal shunt into the stomach, presenting with gastric bleeding. *Acta Neurochir (Wien)* 2007; 149(12): 1269–1270. doi: 10.1007/s00701-007-1413-9.
8. Low SW, Sein L, Yeo TT et al. Migration of the abdominal catheter of a ventriculoperitoneal shunt into the mouth: a rare presentation. *Malays J Med Sci* 2010; 17: 64–67.
9. Aydoseli A, Tahta A, Aras Y et al. Use of antifibrotics to prevent ventriculoperitoneal shunt complications due to intra-abdominal fibrosis: experimental study in a rat model. *J Neurol Surg A Cent Eur Neurosurg* 2015; 76(3): 219–223. doi: 10.1055/s-0034-1389369.
10. Pillai SV. Techniques and nuances in ventriculoperitoneal shunt surgery. *Neurol India* 2021; 69 (Suppl): S471–S475. doi: 10.4103/0028-3886.332261.

38. SLOVENSKÝ A ČESKÝ NEUROLOGICKÝ ZJAZD

37. SLOVENSKO-ČESKÝ EPILEPTOLOGICKÝ ZJAZD

26. – 28. 11. 2025
Hotel Hilton Košice

www.scnz2025.sk

Tešíme sa na vás v Košiciach

