

Can different type of the pressure ulcers debridement affect oxidative stress parameters?

Ovlivní typ nekrektomie dekubitů parametry oxidativního stresu?

Abstract

Wound debridement is one of the crucial steps in wound bed preparation for surgical closure. Various debridement forms and tools can be employed. *Aim:* The prospective case series study aimed to compare the impact of two different types of debridement on oxidative stress parameters. *Material and methods:* This study included five patients with pressure ulcers of deep category various localisation. The wound was divided into halves. In one, the sharp debridement was performed, in the second Hydrosurgery Versajet® debridement was accomplished. Tissue, blood and urine samples were collected on days 0 and 7 after the surgery. Histopathological evaluation in tissue samples was performed. Oxidative stress parameters in plasma and urine were evaluated. *Results:* Differences in quality and quantity of granulation tissue between two types of debridement were found. An insignificant decrease of oxidative stress markers in blood plasma and urine 7 days after surgery were observed. *Conclusions:* Preliminary and pilot results suggest that the wound healing process is closely associated with markers of oxidative stress that are measurable in blood plasma and urine. These could be indicative of the healing process. A nonsignificant decrease was observed for all oxidative stress parameters on day 7 after the surgery. The pilot study will be followed by a detailed molecular biological analysis of tissue samples.

Souhrn

Debridement je jedním z nejdůležitějších kroků k přípravě rány před chirurgickým uzávěrem, který může být proveden v různých formách a různými nástroji. *Cíl:* Cílem prospektivní případové studie bylo porovnat vliv dvou různých typů debridementu (nekrektomie) na parametry oxidativního stresu. *Soubor a metodika:* Do studie bylo zařazeno celkem pět pacientů s hlubokými dekubity v různých lokalizacích. Dekubitus byl rozdělen na dvě poloviny; jedna polovina rány byla ošetřena ostrou nekrektomií a druhá Versajet® hydrosystémem. Vzorů tkání, krve a moči byly odebrány v nultý a sedmý den po debridementu. Byla provedena histopatologická analýza a vyšetření parametrů oxidativního stresu v plazmě a moči. *Výsledky:* Byly nalezeny rozdíly v kvalitě a kvantitě granulační tkáně mezi dvěma různými typy provedení debridementu. Zjištěno bylo nesignifikantní snížení markerů oxidativního stresu v plazmě a moči sedmý den po debridementu. *Závěr:* Předběžné a pilotní výsledky naznačují, že proces hojení ran je úzce spojen s markery oxidativního stresu, které jsou měřitelné v krevní plazmě i v moči. Tyto by mohly poukazovat na průběh hojení. U všech parametrů oxidativního stresu bylo pozorováno nesignifikantní snížení sedmý den po zákroku. Na pilotní studii naváže podrobná molekulárně-biologická analýza vzorků tkáně.

The Editorial Board declares that the manuscript met the ICMJE "uniform requirements" for biomedical papers.

Redakční rada potvrzuje, že rukopis práce splnil ICMJE kritéria pro publikace zasílané do biomedicínských časopisů.

P. Šín¹, A. Hokynková¹,
M. Nováková², H. Paulová³,
P. Babula², A. Pokorná⁴,
L. Nártová¹, P. Coufal¹,
M. Hendrych⁵

¹ Department of Burns and Plastic Surgery, Faculty of Medicine, Masaryk University and University Hospital, Brno

² Department of Physiology, Faculty of Medicine, Masaryk University, Brno

³ Department of Biochemistry, Faculty of Medicine, Masaryk University, Brno

⁴ Department of Health Sciences, Faculty of Medicine, Masaryk University, Brno

⁵ First Department of Pathology, St. Anne's University Hospital Brno and Faculty of Medicine, Masaryk University, Brno



Alica Hokynková, MD, PhD
Department of Burns
and Plastic Surgery
Faculty of Medicine
Masaryk University and University
Hospital
Jihlavská 20
625 00 Brno
e-mail: alicah@post.cz

Key words

pressure ulcer – pressure injury – debridement – Versajet hydrosurgery system – oxidative stress parameters

Klíčová slova

dekubitus – tlakové poranění – debridement – Versajet hydrosystém – parametry oxidativního stresu

Introduction

Surgical treatment of pressure ulcers (PUs) is primarily intended for PUs of a deep category (III and IV category). Meticulous surgical preparation of wounds in various debridement approaches is necessary for successfully reconstructing PUs [1–3] and represents the most crucial technique in wound management [4,5]. By eliminating bacterial colonisation, debridement decreases an inflammatory response and the risk of sepsis [6]. Moreover, it reduces exudate and odour [7] and improves wound healing [8]. Sharp debridement (using scalpel, scissors or electrocautery) [9] was described in 1950 by Cannon et al [10]. Nowadays, it is mainly used type of debridement in PUs surgical therapy. Other debridement techniques were introduced, such as enzymatic [11], ultrasonic [12], Versajet Hydrosurgery system [13], etc. The decision of which type of debridement should be used depends on the wound size, localisation, character of present avital tissue (thickness of eschar, slough, debris etc.) and on preferences and experience of the surgeon.

Hydrosurgery debridement is based on a high-powered jet of saline, enabling cutting tissue simultaneously with a suction of debrided particles which diminishes an aerosolisation effect in the wound [9]. Nu-

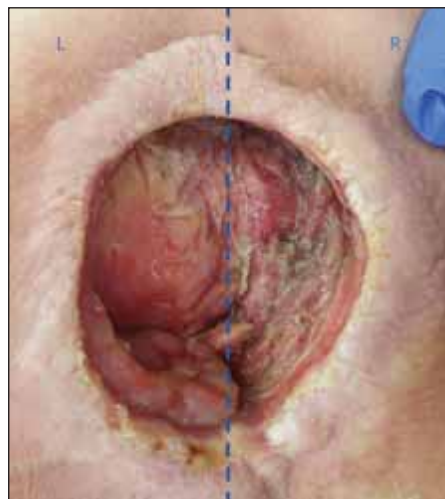

Fig. 1. Macroscopic differences in quality and quantity of granulation tissue in left part of the wound treated by Versajet® hydrosurgery and right part treated by sharp debridement.

Obr. 1. Makroskopické změny v kvalitě a kvantitě granulační tkáně v levé polovině rány (debridement proveden Versajet® hydrosystémem) a v pravé polovině rány (ošetřeno chirurgickou ostrou nekrektomií).

merous studies indicate that reactive oxidative species (ROS) are involved in the wound healing process [14–16]. Aim of the present study was to compare the impact of two different types of debridement on oxidative stress parameters in tissue samples from the same PU. Conventional sharp debridement using scalpel and hydrosurgery Versajet system were compared.

Material and methods

This study included five patients with PUs of deep category (III and IV) and various localisation (sacral, trochanteric and ischial). All these patients were indicated to the surgical therapy. The wound was divided into halves. In one half, the sharp debridement and the second half debridement using Hydrosurgery Versajet® were performed. Tissue samples were harvested before debridement from each half in the first phase and the same place one week after debridement, immediately before surgical closure using flap (fasciocutaneous or musculocutaneous) reconstruction. Tissue samples (3) were fixed in formalin and routinely processed into formalin-fixed paraffin-embedded tissue specimens. Histopathological evaluation of tissue samples was performed using hematoxylin-eosin staining and immunohistochemical analysis of alpha-smooth muscle actin (Abcam, Czech Republic). Blood samples were collected on day 0 and day 7 after the necrectomy. After blood processing and deproteinization (10kD Spin Column, Abcam, Czech Republic, ab93349), the thiols in plasma samples were measured fluorimetrically using 7-azido-4-methylcoumarin as a fluorescent probe ($\lambda_{ex} = 365$ nm and $\lambda_{em} = 450$ nm; Sigma-Aldrich, USA). The method was optimized for plasma samples. The amount of reactive nitrogen species was measured using the enzymatic conversion of nitrate to nitrite by nitrate reductase, followed by the addition of 2,3-diaminonaphthalene (DAN, Sigma-Aldrich, USA), and NaOH, which converts nitrite to a fluorescent compound ($\lambda_{ex} = 365$ nm and $\lambda_{em} = 450$ nm). Total oxidation stress was measured fluorimetrically using 2',7'-dichlorodihydrofluorescein compound ($\lambda_{ex} = 492$ nm and $\lambda_{em} = 515$ nm; Sigma-Aldrich, USA). The amount of hydrogen peroxide was measured using a fluorimetric hydrogen peroxide assay kit (Sigma-Aldrich, USA, MAK165). Morning urine samples were collected at the same time points as blood samples. Urinary 8-hydroxy-2'-deoxyguano-

sine (8-OHdG) was quantified by liquid chromatography with tandem mass spectrometry (triple quadrupole EVOQ CUBE, Bruker, Germany) after SPE purification.

Results

In most cases, a significant difference in the quality of debridement between both types of necrectomy was observed. With hydrosurgery using Versajet®, adequate debridement was obtained in one session only in all cases. In contrast, sharp debridement parts often required further wound bed re-evaluation or debridement during the observed period.

The clinically significant difference in wound bed appearance was also detected after use of Versajet® hydrosurgery, with macroscopically visible signs of improved healing in the form of pink granulation tissue, as shown on the left side in Fig. 1. This difference was even more visible in deep convex surfaces, where effective sharp debridement is technically hard to achieve. It was possible to obtain a macroscopically clean wound bed with overall petechial bleeding even in these complex wounds.

Histopathological analysis of 3 patient's tissue samples revealed granulation tissue without any significant morphological differences in Versajet technique therapy treated samples and sharp surgery. Immunohistochemical expression of alpha-smooth muscle actin displayed increase in smooth muscle cells within the newly formed vessels and stromal myofibroblasts between the first and second tissue samples. No significant differences in different therapy technique were detected (Fig. 2).

Blood analysis was focused on oxidative stress parameters. The results obtained indicate a decrease in the levels of total oxidative stress ($68,456.7 \pm 15,498.5$ A.U. for day 0, $58,459.2 \pm 8,889.00$ A.U. for day 7, respectively), hydrogen sulphide (106.54 ± 20.71 nmol.l⁻¹ for day 0, 101.90 ± 14.06 nmol.l⁻¹ for day 7, respectively), hydrogen peroxide (3.40 ± 2.91 μ mol.l⁻¹ for day 0, 2.73 ± 1.56 μ mol.l⁻¹ for day 7, respectively), and reactive nitrogen species ($12,585.9 \pm 7,806.2$ A.U. for day 0, $9,993.8 \pm 4,400.7$ A.U. for day 7, respectively) on day 7 as compared to day 0. However, this decrease was insignificant (Fig. 3). There was an insignificant decrease in the level of 8-hydroxy-2'-deoxyguanosine, a marker of oxidative stress, on day 7 as compared to day 0 (8.63 ± 2.12 ng/mg creatinine for day 0, 8.10 ± 2.41 ng/mg creatinine for day 7, respectively; for details, see Fig. 4).

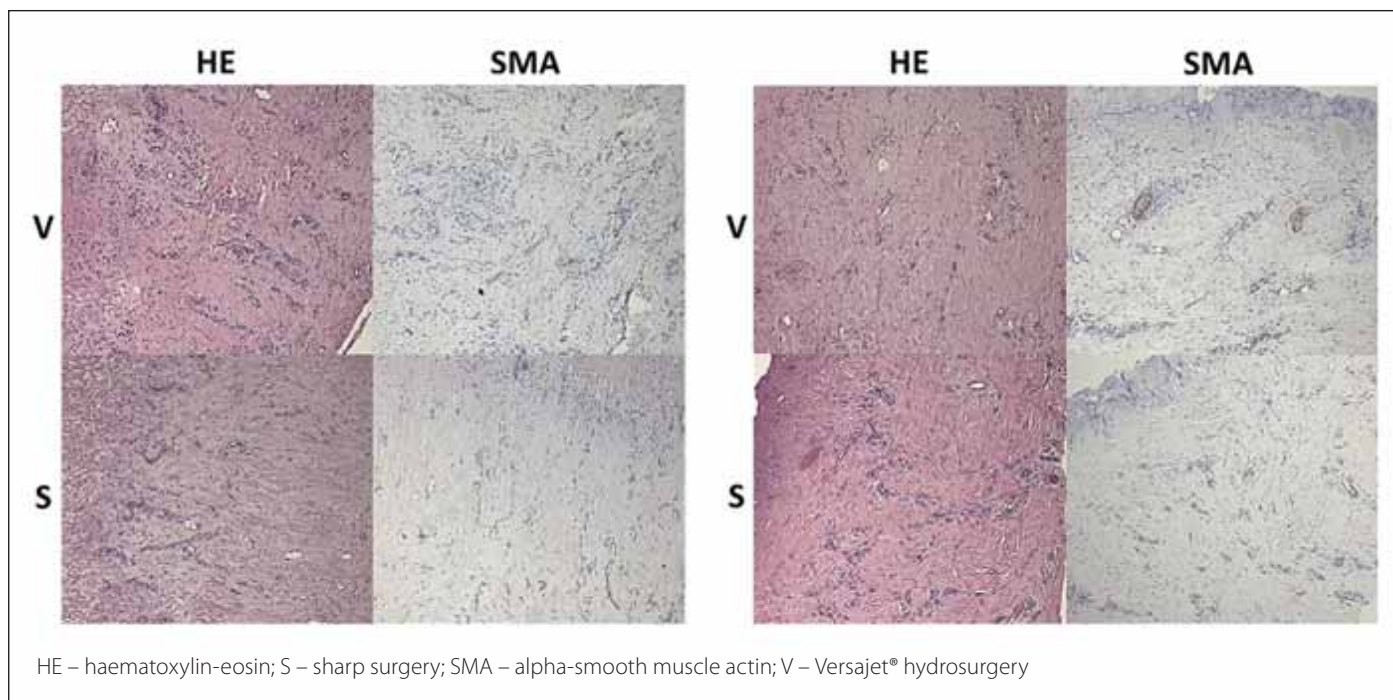


Fig. 2. Histopathological evaluation of tissue samples. Mag. 100x.

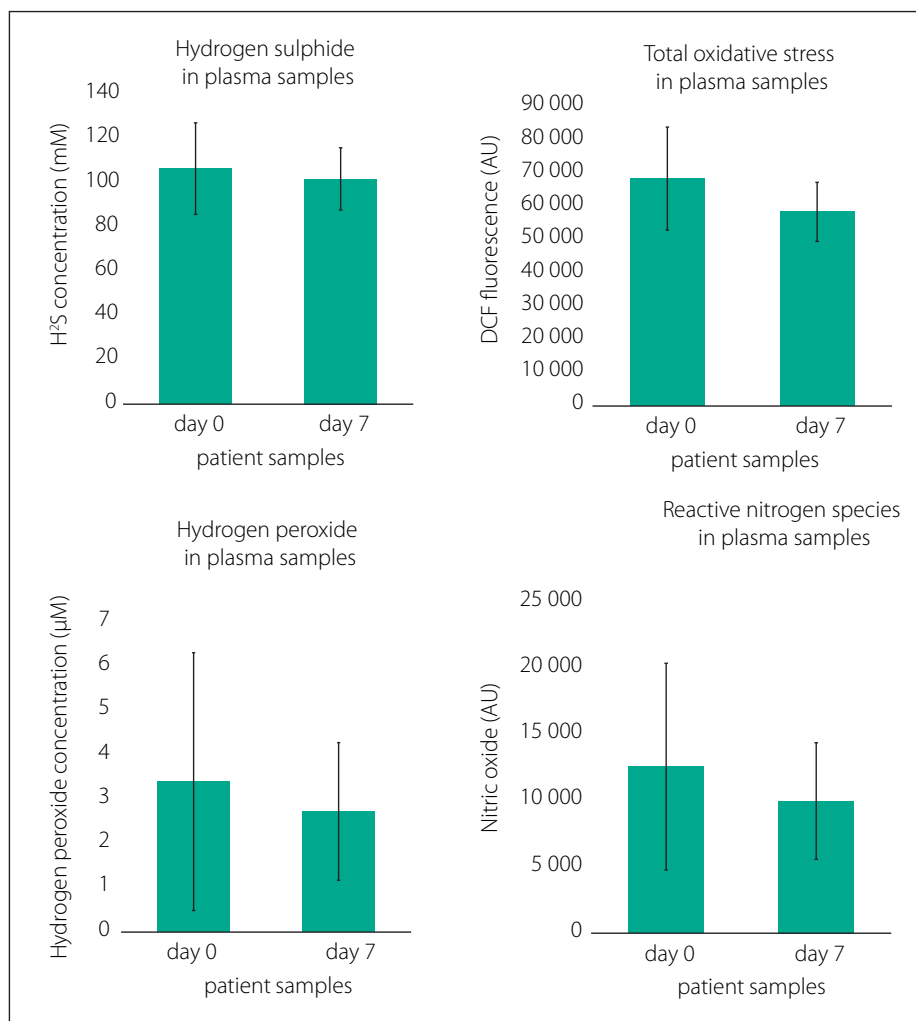
Obr. 2. Histopatologické vyšetření vzorků tkáně. Zvětšeno 100x.

Discussion

Wound healing is a complex process involving the orchestration of different hormones, growth factors and cytokines [15]. Among the crucial compounds playing a role in wound healing, reactive oxygen species can be found. They are implemented simultaneously in several lines. Due to their toxicity, they are an essential component of protection against pathogenic organisms while at the same time playing a vital signalling role in a wide range of processes [16]. Whereas the importance of reactive oxygen species in wound healing has been intensely studied, data showing their relationship to changes in circulating reactive oxygen species (in blood plasma) concerning wound healing processes have not yet been elucidated. The work of James et al showed a correlation between allantoin and uric acid concentrations in patients suffering from leg ulcers [17]. Significant elevation between al-

Fig. 3. Concentrations of hydrogen sulfide and hydrogen peroxide and total oxidative stress parameters and reactive nitrogen species in plasma at day 0 and day 7 after surgery (N = 7).

Obr. 3. Koncentrace hydrogen sulfidu a hydrogen peroxidu, parametry oxidativního stresu a reaktivních forem dusíku v plazmě ve dnech 0 a 7 po operaci (n = 7).



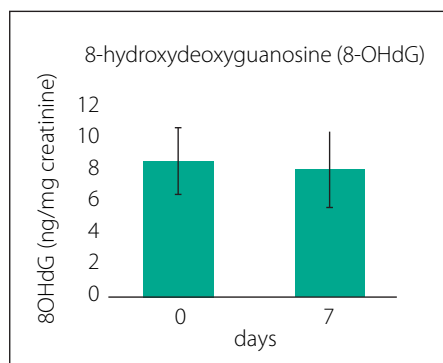


Fig. 4. Changes in concentration of 8-hydroxydeoxyguanosine in urine at day 0 and day 7 after surgery (N = 10).

Obr. 4. Změny koncentrace 8-hydroxy-2'-deoxyguanosin v moči ve dnech 0 and 7 po operaci (n = 10).

lantoin: uric acid percentage ratio was observed in wound fluid from chronic leg ulcer compared to both paired plasma and acute surgical wound fluid. Pressure ulcers development was also studied in an animal model. The elevated level of 8-OHdG was detected in prolonged compressed muscles in mice indicating increased oxidative stress [18]. Moseley et al. discuss the roles of ROS/antioxidants in skin wound healing, their possible involvement in chronic wounds and the potential value of ROS-induced biomarkers in wound healing prognosis [19]. However, the study focuses on the analysis of wound fluids, emphasising total protein carbonyl content, western blot analysis of protein carbonyl content, malondialdehyde content, and total antioxidant capacity in wound fluids. The present study focused on the analysis of blood plasma and urine. The results indicate a decrease of determined markers of oxidative stress in blood plasma and urine on the 7th day after Versajet®/sharp surgery. However, the observed decrease is insignificant. The presented results become from a pilot study; we plan to extend the number

of patients included in the study. Then the significance of the results may be expected.

On the other hand, the results indicate the importance of oxidative stress parameters and their changes concerning wound healing. Next, it will be necessary to correlate the obtained data with other outcomes, such as biochemical parameters and blood analysis. In addition, the study will be extended to include gene expression analysis of candidate genes associated with ROS and selected enzyme activities and markers of oxidative stress in tissue samples.

Conclusions

The pilot study results indicate that wound healing is closely connected to amounts of reactive oxygen and nitrogen species and total antioxidant capacity in corresponding tissue.

Ethical aspects

Institutional Ethical Committee approved this study of Faculty Hospital Brno (Reference Number 17-100620/EK, Project Number 68/20, date 14. 6. 2020).

Acknowledgement

This work was supported by the Ministry of Health of the Czech Republic under grant No. NU21-09-00541 "The role of oxidative stress in the healing of pressure ulcers in patients with spinal cord lesions". All rights reserved.

Conflict of interest

The authors declare they have no potential conflicts of interest concerning drugs, products, or services used in the study.

References

1. Agren MS, Strömberg HE. Topical treatment of pressure ulcers. A randomized comparative trial of Varidase and zinc oxide. *Scand J Plast Reconstr Surg* 1985; 19(1): 97–100. doi: 10.3109/02844318509052871.
2. Hokynková A, Šin P, Černoch F et al. Employment of flap surgery in pressure ulcers surgical treatment. *Cesk Slov Neurol N* 2017; 80/113 (Suppl): S41–S44. doi: 10.14735/amcsnn2017S41.
3. Černoch F, Jelínková Z, Rotschein P. Reconstruction of recurrent ischiadic pressure ulcer using turn-

over hamstring muscle flap. *Cesk Slov Neurol N* 2019; 82/115 (Suppl): S15–S18. doi: 10.14735/amcsnn2019S15.

4. Ligresti C, Bo F. Wound bed preparation of difficult wounds: an evolution of the principles of TIME. *Int Wound J* 2007; 4(1): 21–29. doi: 10.1111/j.1742-481X.2006.00280.x.
5. Pilcher M. Wound cleansing: a key player in the implementation of the TIME paradigm. *J Wound Care* 2016; 25 (Suppl S): S7–S9. doi: 10.12968/jowc.2016.25.Sup3.S7.
6. Longe RL. Current concepts in clinical therapeutics: pressure sores. *Clin Pharm* 1986; 5(8): 669–681.
7. Baranoski S. Pressure ulcers: a renewed awareness. *Nursing* 2006; 36(8): 36–42. doi: 10.1097/00152193-200608000-00037.
8. Schiffman J, Golinko MS, Yan A et al. Operative debridement of pressure ulcers. *World J Surg* 2009; 33(7): 1396–1402. doi: 10.1007/s00268-009-0024-4.
9. Shimada K, Ojima Y, Ida Y et al. Efficacy of Versajet hydro-surgery system in chronic wounds: a systematic review. *Int Wound J* 2021; 18(3): 269–278. doi: 10.1111/iwj.13528.
10. Cannon B, O'leary JJ, O'neil JW et al. An approach to the treatment of pressure sores. *Trans Meet Am Surg Assoc Am Surg Assoc* 1950; 68: 439–457.
11. Rosenberg L, Krieger Y, Bogdanov-Berezovski A et al. A novel rapid and selective enzymatic debridement agent for burn wound management: a multi-center RCT. *Burns* 2014; 40(3): 466–474. doi: 10.1016/j.burns.2013.08.013.
12. Messa CA 4th, Chatman BC, Rhemtulla IA et al. Ultrasonic debridement management of lower extremity wounds: retrospective analysis of clinical outcomes and cost. *J Wound Care* 2019; 28 (Suppl 5): S30–S40. doi: 10.12968/jowc.2019.28.Sup5.S30.
13. Matsumura H, Nozaki M, Watanabe K et al. The estimation of tissue loss during tangential hydrosurgical debridement. *Ann Plast Surg* 2012; 69(5): 521–525. doi: 10.1097/SAP.0b013e31826d2961.
14. Dunnill C, Patton T, Brennan J et al. Reactive oxygen species (ROS) and wound healing: the functional role of ROS and emerging ROS-modulating technologies for augmentation of the healing process. *Int Wound J* 2017; 14(1): 89–96. doi: 10.1111/iwj.12557.
15. Schäfer M, Werner S. Oxidative stress in normal and impaired wound repair. *Pharmacol Res* 2008; 58(2): 165–171. doi: 10.1016/j.phrs.2008.06.004.
16. Hokynková A, Babula P, Pokorná A et al. Oxidative stress in wound healing – current knowledge. *Cesk Slov Neurol N* 2019; 82/115 (Suppl 1): S37–S39. doi: 10.14735/amcsnn2019S37.
17. James TJ, Hughes MA, Cherry GW et al. Evidence of oxidative stress in chronic venous ulcers. *Wound Repair Regen* 2003; 11(3): 172–176. doi: 10.1046/j.1524-475x.2003.11304.x.
18. Wong SW, Cheung BC, Pang BT et al. Intermittent vibration protects aged muscle from mechanical and oxidative damage under prolonged compression. *J Biomech* 2017; 55: 113–120. doi: 10.1016/j.jbiomech.2017.02.023.
19. Moseley R, Hilton JR, Waddington RJ et al. Comparison of oxidative stress biomarker profiles between acute and chronic wound environments. *Wound Repair Regen* 2004; 12(4): 419–429. doi: 10.1111/j.1067-1927.2004.12406.x.