

doi: 10.14735/amcsnn2020436

# Carotid body paraganglioma, a very rare pediatric tumor

## Karotický paragangliom, velmi vzácný nádor v dětském věku

Dear editorial office,

The carotid body tumor (CBT) is the most common paraganglioma (PG) that occurs in the neck; it accounts for almost 60% of head and neck PGs [1]. This neoplasm arises from neural crest-derived ectoderm in the third branchial arch. It is located in the adventitia of the carotid bifurcation. CBT is benign in 90–95% of cases, and it is typically identified accidentally as a unilateral, painless, slow-growing mass on the neck [2,3]. Only about 10% of patients have bilateral tumors [4].

A neck mass is often observed in infants and children. The differential diagnosis must consider many different diseases, including lymphomas, branchial cleft cysts, metastatic lymph nodes, etc. Although tumors involving blood vessels are not uncommon in children, CBTs are extremely rare in pediatric patients. The world literature has reported less than 20 cases of CBTs in children under the age of 14 [5]. This case study describes one.

A 13-year-old girl with a painless mass in the right upper neck area was referred to the Department of Otorhinolaryngology. She had a 7-year history of a slow-growing swelling that first appeared at the age of 6, which raised the suspicion of a lateral neck cyst or lymphadenopathy. Clinical examination showed a 3- to 4-cm painless mass on the right side of the neck just below the angle of the mandible, at the level of the hyoid bone. The mass was mobile in the horizontal plane, but not in the vertical plane. There were no signs of cranial nerve lesions.

A Doppler US examination demonstrated a tumor 4 × 3 × 3.5 cm in size, with hypervascularization on the right side of the carotid bifurcation. Normal perfusion was observed in the internal and external carotid arteries. The tumor was adjacent to the submandibular gland. MRI confirmed that it was a tumor at the carotid bifurcation that had not infiltrated the surrounding tissues. We observed a hyperintense signal in T2-weighted images and a distinct contrast enhancement in T1-weighted images (Fig. 1). Carotid arteri-

ography showed a highly vascularized tumor at the carotid bifurcation with afferent vessels emerging from the external carotid artery and ascending pharyngeal artery (Fig. 2). We did not perform a temporary balloon occlusion test. Angiography was performed under general anesthesia, prior to surgery, with Vortex coils 2/3 (2 pieces) and 2/4 (2 pieces) and Deltaplus coils 2/3 and 2/4 for embolization. Then, with continued anesthesia, the patient was transferred to the operating theater for surgery.

Surgery was performed by a head and neck surgeon and neurosurgeon. The jugular vein and vagal nerve were exposed, and the carotid arteries were dissected and pulled aside. The median nerve was stimulated with somatosensory evoked potentials (SEPs) during the operation to monitor cerebral function, and after the surgery to prevent a potential neurologic deficit.

The tumor was separated from the external and internal carotid arteries. The superior thyroid artery and ascending pharyngeal artery were ligated at the point where they emerged from the right side of the carotid bifurcation (a cross stitch was required). It was necessary to clamp the carotid artery for 7 min to perform this part of the surgery. SEP monitoring showed no changes in cerebral function, which suggested that collateral vessels adequately supplied the right side of the brain. The CBT was completely removed.

The patient exhibited no postoperative complications, and the wound healed per primam. The patient was discharged from the hospital 7 days after the surgery. No signs of tumor persistence or recurrence were observed, and no signs of neurological deficit were found during a 24-month follow-up. A genetic examination showed no genetic basis for the CBT in this patient.

These tumors typically occur sporadically; however, they can be associated with a genetic predisposition (familial or hereditary CBT) [6]. They occur most frequently in in-

The Editorial Board declares that the manuscript met the ICMJE "uniform requirements" for biomedical papers.

Redakční rada potvrzuje, že rukopis práce splnil ICMJE kritéria pro publikace zasílané do biomedicínských časopisů.

**M. Formánek<sup>1</sup>, T. Hrbáč<sup>2</sup>,  
V. Procházka<sup>3</sup>, L. Čábalová<sup>1</sup>,  
P. Komínek<sup>1</sup>**

<sup>1</sup> Department of Otorhinolaryngology and Head and Neck Surgery, University Hospital Ostrava, Czech Republic

<sup>2</sup> Department of Neurosurgery, University Hospital Ostrava, Czech Republic

<sup>3</sup> Department of Radiology, University Hospital Ostrava, Czech Republic



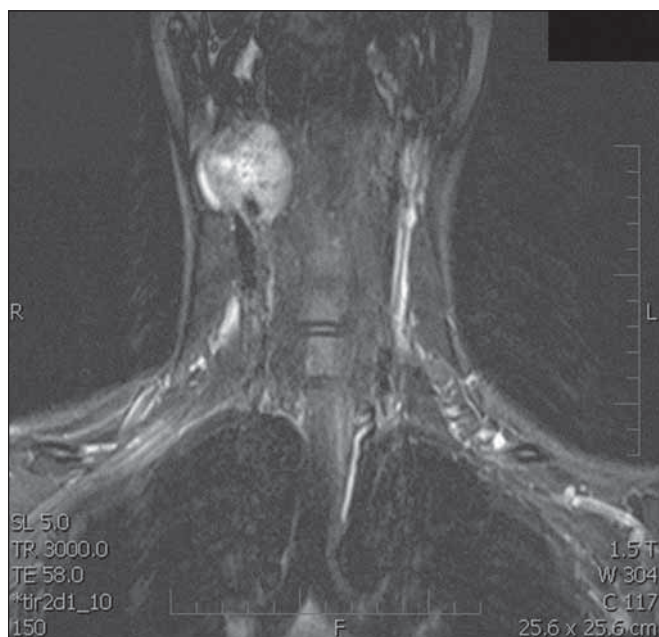
**Martin Formánek, MD, PhD**  
Department of Otorhinolaryngology  
and Head and Neck Surgery  
University Hospital Ostrava  
17. listopadu 1790  
708 52 Ostrava  
Czech Republic  
e-mail address:  
martin.formanek@fno.cz

Accepted for review: 20. 2. 2020

Accepted for print: 14. 5. 2020

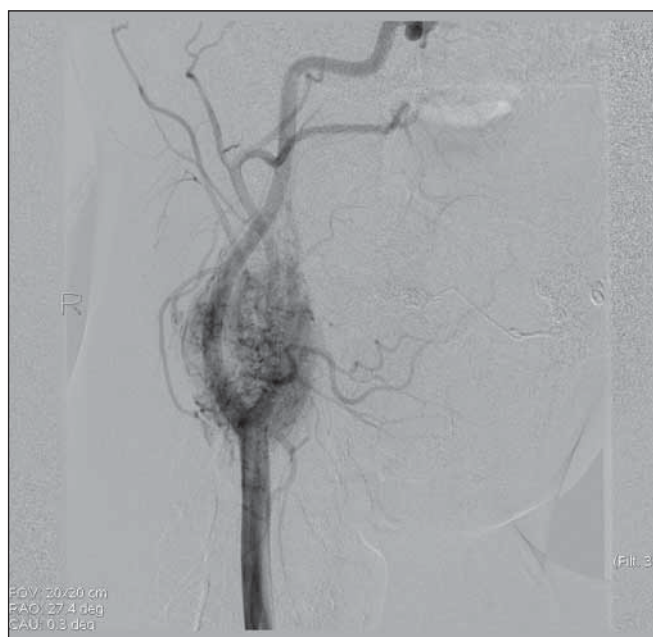
dividuals that reside at high altitudes, where atmospheric oxygen pressure is low; these conditions provide a chronic hypoxic stimulus [3].

Typically, CBT presents as a painless neck mass. Signs of cranial nerve deficits, such as dysphagia, dysphonia, or difficulties with mastication, only occur in 10–30% of patients [2]. In our patient, the CBT presented only as a neck mass with no other accompanying symptoms. A very rare symptom is excessive catecholamine release, which occurs in 1 to 3% of patients [7]. This rare occurrence and the absence of signs of catechola-



**Fig. 1.** T1-weighted MRI scan, after administration of gadolinium, demonstrates a mass within the right carotid space. Both the external carotid artery and the internal carotid artery are constricted.

Obr. 1. T1-vážený obraz MR po podání gadolinia. Viditelná masa karotické prostoru vpravo zaujímající a. carotis externa a interna.



**Fig. 2.** Carotid arteriography shows a strongly vascularized lesion in the right carotid bifurcation with a typical image for paraganglioma.

Obr. 2. Angiografický obraz ukazuje silně vaskularizované ložisko v pravé karotické bifurkaci s typickým obrazem pro paragangliom.

mine release in our patient were the reasons why levels of catecholamines were not assessed preoperatively. The tumor growth is very slow. Usually, the diagnosis is not made until the CBT reaches a palpable volume. Thus, CBTs typically appear in the fourth to sixth decade of life, and they are extremely rare in children [8].

There is no consensus opinion on preoperative embolization, and sometimes this is a controversial issue. Most authors prefer preoperative embolization, because it can significantly reduce intraoperative bleeding [9]. On the other hand, some authors avoid the use of preoperative embolization due to the risk of stroke [10]. In our patient, the preoperative embolization applied had a significant effect on perioperative blood loss, which was minimal. In addition, intraoperative electroencephalographic monitoring is advantageous, because it can reduce the risk of brain injury caused by restricted blood flow through the internal carotid artery. In our patient, even though the internal carotid artery was clamped for several minutes, no neurologic deficit occurred. A specific feature of our treatment was that em-

bolization was followed by surgery during a single general anesthesia administration. This approach reduced the anesthesia duration and the number of anesthesia administrations required.

The carotid body tumor should be considered in the differential diagnosis of a neck mass in older children. We showed that the CBT could be successfully treated with preoperative embolization and surgical resection. Moreover, these procedures could be performed during a single anesthesia administration. When planning an early surgical resection, to avoid major surgery-related complications, the main factors to consider should be the slow growth of CBT, its low malignancy rate, and the high rate of postoperative morbidity in large tumors.

### Acknowledgement

Supported by the Ministry of Health, Czech Republic – conceptual development of research organization (FNOs/2019).

### References

1. Georgiadis GS, Lazarides MK, Tsalkidis A et al. Carotid body tumor in a 13-year-old child: Case report and re-

view of the literature. *J Vasc Surg* 2008; 47(4): 874–880. doi: 10.1016/j.jvs.2007.10.040.

2. Naik SM, Shenoy AM, Nanjundappa et al. Paragangliomas of the carotid body: current management protocols and review of literature. *Indian J Surg Oncol* 2013; 4(3): 305–312. doi: 10.1007/s13193-013-0249-4.

3. Čertík B, Třeška V. Why are carotid glomus tumours dangerous? *Rozhl Chir* 2014; 93(10): 512–515.

4. Amato B, Bianco T, Compagna R et al. Surgical resection of carotid body paragangliomas: 10 years of experience. *Am J Surg* 2014; 207(2): 293–298. doi: 10.1016/j.amjsurg.2013.06.002.

5. Gogoi G, Chelleng KK, Borgohain M et al. Carotid body paraganglioma in a child: a novel experience. *CIBTech J Surg (Online)* 2014; 3: 37–41. doi: 10.1016/j.jvs.2007.10.040.

6. Sridhara SK, Yener M, Hann EY et al. Genetic testing in head and neck paraganglioma: who, what, and why? *J Neurol Surg B Skull Base* 2013; 74(4): 236–240. doi: 10.1055/s-0033-1342924.

7. Offereld C, Brase C, Yaremchuk S et al. Head and neck paragangliomas: clinical and molecular classification. *Clinics (Sao Paulo)* 2012; 67 (Suppl 1): 19–28. doi: 10.6061/clinics/2012(sup01)05.

8. Boscarino G, Parente E, Minelli F et al. An evaluation on management of carotid body tumour (CBT). A twelve years experience. *G Chir* 2014; 35(1–2): 47–51.

9. Litle VR, Reilly LM, Ramos TK. Preoperative embolization of carotid body tumors: when is it appropriate? *Ann Vasc Surg* 1996; 10(5): 464–468. doi: 10.1007/BF02000594.

10. Hallett JW, Nora JD, Hollier JH et al. Trends in neurovascular complications of surgical management of carotid body and cervical paragangliomas: a fifty-year experience with 153 tumors. *J Vasc Surg* 1988; 7(2): 284–291.