

# Focal epileptic seizure in a young female from South Korea

## Fokální epileptický záchvat u mladé ženy z Jižní Korey

Dear editors,

We would like to share with you a rare case of neurocysticercosis observed in a young foreign female in whom the disease manifested with a focal epileptic seizure [1]. Neurocysticercosis is extremely rare in Europe, but common in South Asia or South America, and it is one of the most probable epileptogenic lesions in India [2].

We present the case of a 35-year-old female patient from South Korea with no history of any diseases. When she was going to the toilet at about midnight, her right hand started shaking, she felt rhythmic twitching of the hand, experienced distortion of her face, and allegedly she could not breathe for a while. Subsequently, she felt weakness in her right upper limb for a short time. She did not fall unconscious. She never experienced any such problems before.

The objective baseline neurological finding showed no phatic disorder (clinical examination was limited given the language barrier) and no pathological topical neu-

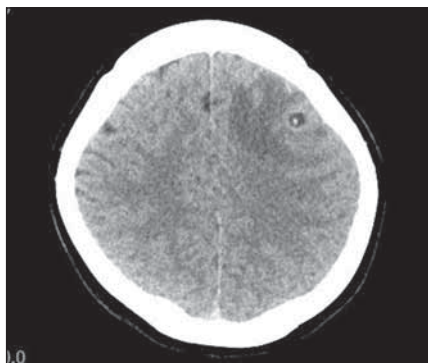
rological finding was present; the patient's tongue was slightly bitten.

Acute laboratory assessments (blood serum) showed no remarkable findings. EEG showed a lower amplitude and no indications of epileptiform pattern. CT imaging of the brain indicated a round-shaped hypodense lesion in the left frontal region, sized 7 mm, with central dot-like hyperdensity and vasogenic oedema. The lesion could correspond to neurocysticercosis (Fig. 1). MRI of the brain showed a cystic ring enhancing lesion in the left frontal region, so far with no regressive changes in terms of calcifications, with distinct perifocal oedema; most likely a granular nodular stage of neurocysticercosis (Fig. 2). CT imaging of the neck, chest, abdomen, and pelvis showed no findings of lymphoproliferation and no cystic or tumorous changes.

Based on the clinical and morphological presentation (CT and MRI of the brain), the condition was diagnosed as neurocysticercosis in the left cerebral hemisphere, manifesting as a focal motor epileptic seizure.

Antiepileptic therapy was administered during hospitalization – levetiracetam 250 mg twice daily with a gradual increase of the dose, and antiedematous therapy – mannitol and corticosteroids. No additional epileptic seizure occurred.

Upon agreement with the National Reference Laboratory, we collected serum samples for tissue helminthoses (serologic evidence of cysticercosis) testing of which was negative. The patient was transferred to the Department of Infectious and Tropical Diseases at Na Bulovce Hospital where she received specific treatment with albendazole and antiedematous therapy in the duration of 2 weeks. Follow-up MRI of the brain 2 weeks later showed a stationary cystic formation in the left frontal region with a small-sized internal nodule and partial regression of the vasogenic oedema; the finding corresponded to the colloidal vesicular stage of neurocysticercosis.



**Fig. 1. CT scan of the brain, transversal image. Round-shaped hypodense lesion in the left frontal region, sized 7 mm, with central dot-like hyperdensity; the lesion corresponds to neurocysticercosis.**

Obr. 1. CT mozku, transversální řez. Kulovité hypodenzní ložisko frontálně vlevo velikosti 7 mm, s centrální tečkovitou hyperdenzitou odpovídá neurocysticerkóze.

The Editorial Board declares that the manuscript met the ICMJE "uniform requirements" for biomedical papers.

Redakční rada potvrzuje, že rukopis práce splnil ICMJE kritéria pro publikace zasílané do biomedicínských časopisů.

**M. Kesslerová, I. Štětkářová,  
Z. Svobodová, T. Peisker**

Department of Neurology, Third Faculty of Medicine, Charles University and University Hospital Královské Vinohrady, Prague, Czech Republic



**Prof. Ivana Stetkarova, MD, PhD**  
Department of Neurology  
Third Faculty of Medicine  
Charles University  
and University Hospital Královské  
Vinohrady  
Šrobárova 1150/50  
100 34 Prague  
Czech Republic  
e-mail: ivana.stetkarova@fnkv.cz

Accepted for review: 9. 4. 2020

Accepted for print: 8. 1. 2020

The patient returned to South Korea. We have no information about her further fate.

Cysticercosis is caused by the tapeworm *Taenia solium* whose larval stage induces cysticercosis in humans [3]. In recent years, the incidence of taeniosis/cysticercosis in the Czech Republic is very low; the total amount of about 10 cases in 1990–2017 [4].

Humans can become infected by consuming eggs of *Taenia solium* by faecal-oral route, e.g., from infected water or food, but also through autoinfection. Cysticerci can occur in many organs, most commonly in the central nervous system, eye, heart or muscles, and in the subcutaneous connective tissue. Clinical symptoms depend on the localization and amount of cysticerci.

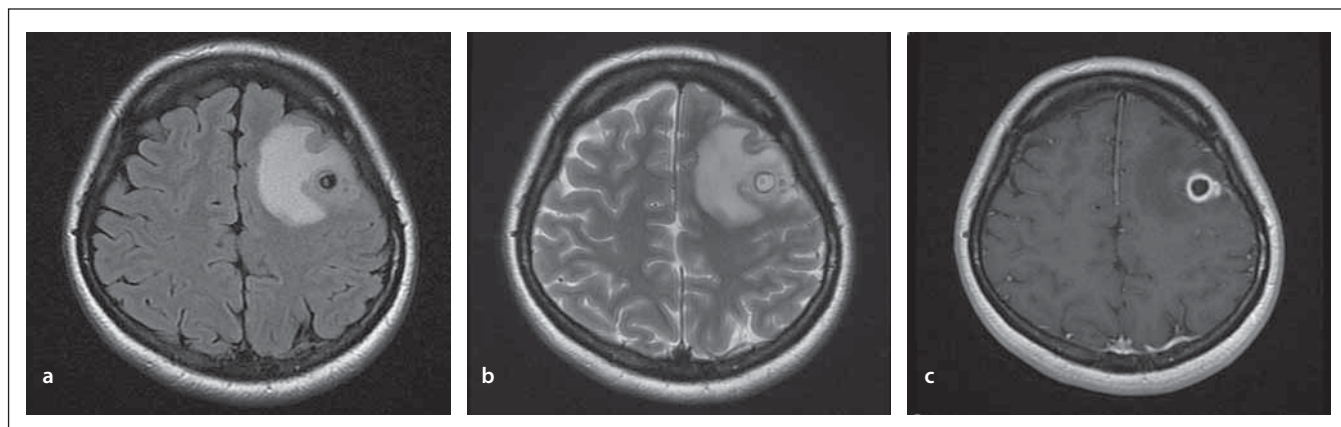


Fig. 2. MRI of the brain, transversal images. Cystic ring enhancing lesion in the left frontal region, with distinct perifocal oedema; most likely a granular nodular stage of neurocysticercosis. (a) T1 weighted image; (b) T2 weighted image; (c) T1 weighted image with gadolinium.

Obr. 2. MR mozku, transversální řezy. Cystické ložisko frontálně vlevo s enhancujícím prstencem, s výrazným perifokálním edémem. Nej-spíše granulárně nodulární stadium neurocystercerkózy. (a) T1 vážený snímek; (b) T2 vážený snímek; (c) T1 vážený snímek s gadoliniem.

Neurocysticercosis is the most serious form [5]; the cysticerci are found in the brain cortex, subarachnoid space, and brain ventricles.

The most common signs include epileptic seizures, intracranial hypertension, meningoencephalitis, or mental disorders. It strongly depends on the number, location, size and evolutionary stage of the lesions, and on the inflammatory response of the host.

Neurocysticercosis has four anatomical stages (vesicular, vesicular-coloidal, granular-nodular, nodular-calcified). The most epileptogenic one is the 2<sup>nd</sup> stage when the cysticercus dies. Neurocysticercosis is a major contributor to the burden of seizure disorders and epilepsy also in most of the world [2,6] as it was observed in our patient. The disease can be diagnosed based

on the presence of antibodies in the serum (ELISA, Western-blot methods). The diagnosis of sporadic larvae is difficult because only low levels of the antibodies are produced. In such a case, the cysticerci can be detected using imaging methods (CT, MRI) that provide relatively typical images [7]. The blood count may also be altered (eosinophilia). The therapy is based on antiparasitic drugs (albendazole, praziquantel); however, this therapy may worsen the inflammation around the cysticercus. If the treatment is ineffective or associated with such complications, surgery needs to be approached.

#### Disclosures

The authors declare they have no potential conflicts of interest concerning drugs, products, or services used in the study.

#### References

1. Štětkařová I. Spinální neurologie. Kazuistika 13.5. Praha: Maxdorf 2019; 280.
2. Murthy JM, Seshadri V. Prevalence, clinical characteristics, and seizure outcomes of epilepsy due to calcific clinical stage of neurocysticercosis: study in a rural community in south India. *Epilepsy Behav* 2019; 98(Pt A): 168–172. doi: 10.1016/j.yebeh.2019.07.024.
3. Garcia HH, Nash TE, Del Brutto OH. Clinical symptoms, diagnosis, and treatment of neurocysticercosis. *Lancet Neurol* 2014; 13(12): 1202–1215. doi: 10.1016/S1474-4422(14)70094-8.
4. Trevisan C, Sotiraki S, Laranjo-González M et al. Epidemiology of taeniosis/cysticercosis in Europe, a systematic review: eastern Europe. *Parasit Vectors* 2018; 11(1): 569. doi: 10.1186/s13071-018-3153-5.
5. Frackowiak M, Sharma M, Singh T et al. Antiepileptic drugs for seizure control in people with neurocysticercosis. *Cochrane Database Syst Rev* 2019; 10: CD009027. doi: 10.1002/14651858.CD009027.pub3.
6. Garcia HH. Neurocysticercosis. *Neurol Clin* 2018; 36(4): 851–864. doi: 10.1016/j.ncl.2018.07.003.
7. Hernández RD, Durán BB, Lujambio PS. Magnetic resonance imaging in neurocysticercosis. *Top Magn Reson Imaging* 2014; 23(3): 191–198. doi: 10.1097/RMR.000000000000026.

An additional attachments of this article can be found on the website csnn.eu.  
Na webu csnn.eu naleznete rozšířené přílohy k tomuto článku.