

Aneurysmal subarachnoid haemorrhage in pregnancy – successful clipping after coiling failure

Aneuryzmatické subarachnoidální krvácení v těhotenství – úspěšný klipování po selhání koilingu

Dear Editor,

Subarachnoid haemorrhage from a cerebral aneurysm (aSAH) in pregnancy is uncommon. The incidence is estimated at 5.8 cases per 100,000 births [1]. The bleeding constitutes a very serious condition for both the mother and the foetus. aSAH is the third most common non-pregnancy cause of maternal mortality during pregnancy and is responsible for severe maternal and foetal morbidity [2]. aSAH mortality is double in untreated patients compared to those who are treated (10.2 vs. 5.2%) [3]. Special consideration must be taken for both the mother and the foetus. Our knowledge is based solely on case reports, as prospective studies are impossible due to both the scarcity of the ailment and ethical objections.

A 29-year-old woman in the 27th week of pregnancy was admitted to hospital with a severe headache. CT revealed aSAH caused by the rupture of the aneurysm in the anterior communicating artery. The decision making required a multidisciplinary discussion involving neurosurgeon, intervention radiologist, neonatologist, obstetrician and anesthesiologist. The likely need for an urgent Caesarian section (CS) was discussed. Therefore, the administration of corticosteroids inducing acceleration of the lung maturation was initiated. The characteristics of the aneurysm – its location, size, shape, the direction of the sac, neck-fundus ratio – required both microsurgical and endovascular treatment. After the discussion, the team decided to favour the endovascular treatment to minimise general anaesthesia duration and risk of hypotension-induced hypoxaemia of the foetus. Radiation load was of significant concern but proved to be acceptable. The coiling was performed without complications (Fig. 1a, b, c).

Both the patient and the child were subsequently in good health. During the 13th postoperative day, brief loss of consciousness and transient hemiparesis suddenly appeared. CT showed a recurrence of the haemorrhage in the interhemispheric fissure. Angiography showed a bilocular aneurysm in the original localization with visible coils at the top of one of the sacs. The recurrence of an aneurysm may be explained by a partial thrombosis of an aneurysm at the time of coiling, followed by the recanalisation of the sac after the thrombus had dissolved. Due to vasospasm of the right middle cerebral artery, the team decided not to continue with further endovascular treatment. At the time of the aSAH recurrence, the foetus was in the 29th week of gestation. Therefore, it was decided to perform a CS with a subsequent aneurysm clipping. After the uncomplicated CS, the neurosurgeon clipped the aneurysm from the right pterional approach. The successful closure of the sac was verified by indocyanine green during the surgery (viz Fig. 2a, b).

The patient was in good clinical condition after the surgery. Mild asymptomatic vasospasm subsided within a few days. One year after the surgery, mother and child were in good condition.

The data proving pregnancy to be a risk factor for the rupture of an aneurysm are ambiguous. The initial assumption that pregnancy does not increase the incidence of bleeding was disputed by Dias et al, who pointed out that the presence of aSAH was rising with the length of gestation [4]. During the pregnancy, the heart rate increases by 60%, blood volume and blood pressure increase continuously until delivery. At the same time, hormone levels such as progesterone, estrogen, gonadotropin and relaxin

The authors declare they have no potential conflicts of interest concerning drugs, products, or services used in the study.

Autoři deklarují, že v souvislosti s předmětem studie nemají žádné komerční zájmy.

The Editorial Board declares that the manuscript met the ICMJE “uniform requirements” for biomedical papers.

Redakční rada potvrzuje, že rukopis práce splnil ICMJE kritéria pro publikace zasílané do biomedicínských časopisů.

J. Dostál¹, V. Přibáň¹, J. Mraček¹, P. Vacek¹, P. Duras²

¹ Neurochirurgická linka
LF UK a FN Plzeň

² Klinika zobrazovacích metod
LF UK a FN Plzeň



doc. MUDr. Vladimír Přibáň, Ph.D.
Neurochirurgická klinika LF UK
a FN Plzeň
Alej Svobody 80
304 60 Plzeň
e-mail: pribanv@fnplzen.cz

Accepted for review: 15. 11. 2018

Accepted for print: 25. 1. 2019

increase, which may predispose a patient to the onset, growth, and potential rupture of an aneurysm. In the third trimester, aSAH occurs at 77%, compared with 8% in the first trimester and 11% in the second trimester. [5]. Therefore, screening of high-risk pregnant women is important. Kataoka et al lists chronic hypertension and a history of stroke among the risk factors. Auxiliary risk factors include obesity, age over 40 years,

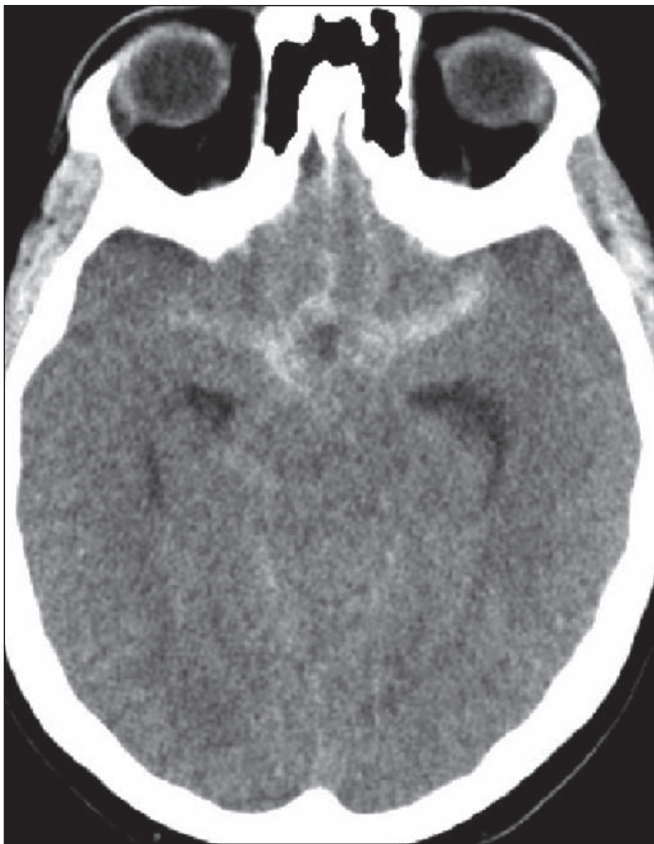

Fig. 1a. Subarachnoid hemorrhage in the basal cisterns in a non-contrast CT scan of the brain.

Obr. 1a. Subarachnoidální krvácení v bazálních cisternách na nativní CT mozku.

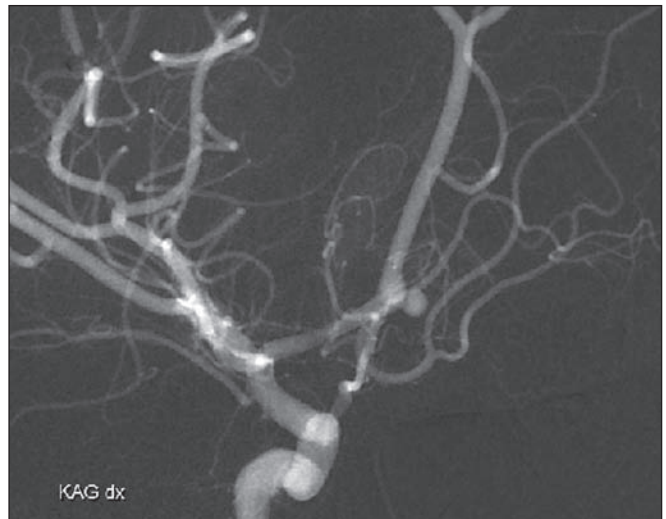


Fig. 1b. DSA – anterior-oriented aneurysm of the anterior communicating artery.

Obr. 1b. DSA – dopředu mířící aneuryzma přední komunikující tepny.

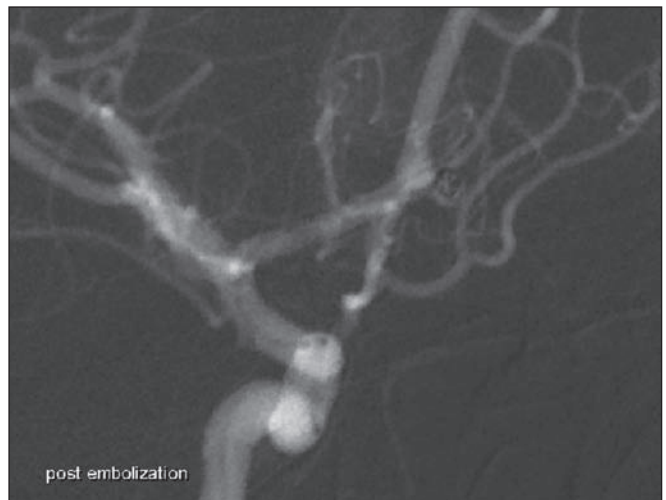

Fig. 1c. Successful embolisation of the aneurysm.

Obr. 1c. Úspěšná embolizace aneuryzmatu.

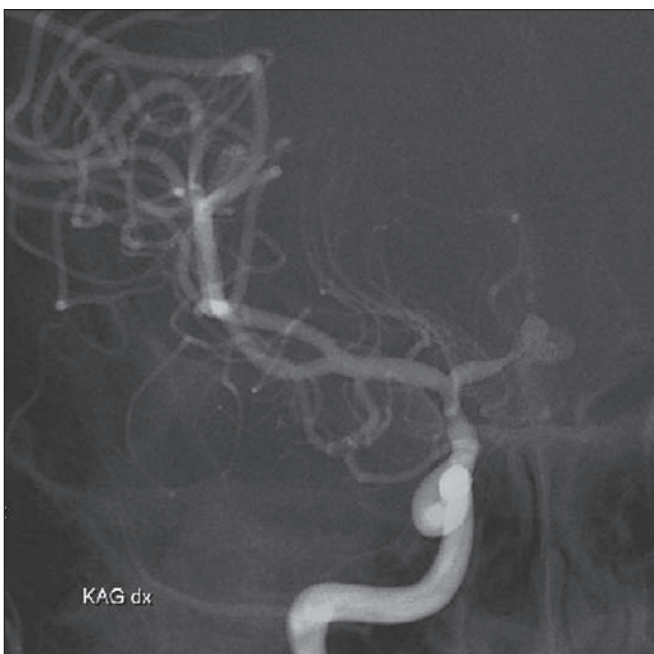

Fig. 2a. Recanalisation of the aneurysm in angiography. A bilocular aneurysm with coils pressed against the top of the fundus.

Obr. 2a. Rekanalizace aneuryzmatu na angiografii. Bilokulární aneuryzma s koily, vytlačenými do vrcholu fundu.

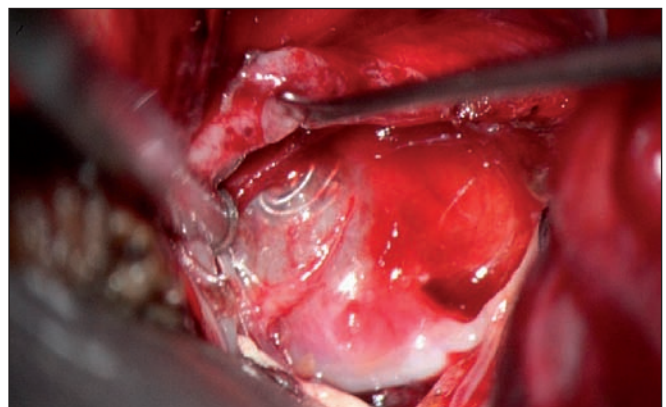


Fig. 2b. Intraoperative finding of the aneurysmal sac with coils showing through in a lumen.

Obr. 2b. Peroperační nález stěny aneuryzmatu s patrnými koily v lumen vaku.

chronic headache, pregnancy hypertension and a family history of stroke. The presence of two or more auxiliary risk factors is an indication for MRA [6]. In the case of a finding of a non-ruptured aneurysm in pregnancy, we have to decide whether to intervene. An active approach is recommended for aneurysms larger than 5 mm, growing, of irregular shape, with secondary sacs and in "risk locations" (posterior circulation, anterior and posterior communicating arteries). Symptomatic aneurysms are also indicated for treatment. [7]. As for diagnostic methods, CT is the dominant method followed by CTA. In an attempt to avoid the radiation burden, the authors have recently preferred to perform MRA. For the same reason, they prefer clipping as a treatment method; coiling is acceptable following the delivery when the radiation does not burden the foetus [8]. However, if the protection of the foetus is performed correctly, the radiation load is below teratogenic doses in both the diagnostic angiography and the endovascular treatment [9]. When treating a ruptured aneurysm, we generally can select from microsurgical and endovascular treatment. The advantage of coiling is usually a shorter duration of general anaesthesia. The disadvantage is the above-mentioned radiation burden, especially in the first trimester. Another

disadvantage is the need for systemic administration of heparin and risk of haemorrhage [9]. Both methods are now generally perceived as equal and deciding on the type of treatment should be individual. It is determined by the location of the aneurysm, its size, shape, direction and neck-fundus ratio [10]. There are no guidelines for the treatment of aSAH during pregnancy, and it is impossible to stipulate any. Nevertheless, in the first and second trimesters, a ruptured aneurysm is to be treated as if the patient was not pregnant. In the third trimester, decision making is individual. From the 34th week of gestation up to the delivery date, the CS is preferred initially, followed by the ruptured aneurysm treatment. The occurrence of an aneurysm on the verge of the second and third trimester up to the 34th week gives the possibility to treat the aneurysm without terminating the pregnancy. CS at term is dominant over vaginal delivery also in this case. [5,9]. Obstetricians and neonatologists should decide on preterm delivery and its method. Treatment of a ruptured aneurysm in pregnancy is not standardized. The solution is always individual and interdisciplinary.

References

1. Bateman BT, Olbrecht VA, Berman MF et al. Peripartum subarachnoid hemorrhage: nationwide data and institutional experience. *Anesthesiology* 2012; 116(2): 324–333. doi: 10.1097/ALN.0b013e3182410b22.
2. Stoodly MA, Macdonald RL, Weir BK. Pregnancy and intracranial aneurysms. *Neurosurg Clin N Am* 1998; 9(3): 549–556.
3. Kim YW, Neal D, Hoh BL. Cerebral aneurysms in pregnancy and delivery: pregnancy and delivery do not increase the risk of aneurysm rupture. *Neurosurgery* 2013; 72(2): 143–149. doi: 10.1227/NEU.0b013e3182796af9.
4. Dias MS, Sekhar LN. Intracranial hemorrhage from aneurysms and arteriovenous malformations during pregnancy and puerperium. *Neurosurgery* 1990; 27(6): 855–865.
5. Barbarite E, Hussain S, Dellarole A et al. The management of intracranial aneurysms during pregnancy: a systematic review. *Turk Neurosurg* 2016; 26(4): 465–474. doi: 10.5137/1019-5149.JTN.15773-15.0.
6. Kataoka H, Miyoshi T, Neki R et al. Subarachnoid hemorrhage from intracranial aneurysms during pregnancy and the puerperium. *Neurol Med Chir (Tokyo)* 2013; 53(8): 549–554.
7. Tanaka H, Katsuragi S, Tanaka K et al. Impact of pregnancy on the size of small cerebral aneurysm. *J Matern Fetal Neonatal Med* 2017; 30(22): 2759–2762. doi: 10.1080/14767058.2016.1262345.
8. Fritzsche FS, Regelsberger J, Schmidt NO et al. Maternal aneurysmal subarachnoid hemorrhage during pregnancy as an interdisciplinary task. *Z Geburtsh Neonatol* 2017; 221(6): 276–282. doi: 10.1055/s-0043-119363.
9. Robba C, Bacigaluppi S, Brazzagi F et al. Aneurysmal subarachnoid hemorrhage in pregnancy – case series, review and pooled data analysis. *World Neurosurg* 2016; 88: 383–398. doi: 10.1016/j.wneu.2015.12.027.
10. Marshman LA, Aspoas AR, Rai MS et al. The implication of ISAT and ISUIA for the management of cerebral aneurysms during pregnancy. *Neurosurg Rev* 2007; 30(3): 177–180. doi: 10.1007/s10143-007-0074-8.

Please visit csnn.eu for additional attachments to this article.
Na webu csnn.eu naleznete další přílohy k tomuto článku.