

Association between surgical results and recurrence in benign and intermediate osteogenic spine tumors – osteoid osteomas and osteoblastomas

Souvislost mezi výsledky operace a rekurencí benigních a intermediárních osteogenních tumorů páteře – osteoidních osteomů a osteoblastomů

Abstract

Background: Osteoma and osteoid osteoma are classified as benign subtypes of osteogenic spinal tumors, and osteoblastoma is classified as an intermediate subtype. This study aimed to present our surgical approach for patients with these tumors and to provide information about the relationship between surgical treatment and recurrence. **Methods:** Eighteen patients who underwent surgery in our department were retrospectively evaluated. Demographic characteristics, presentation complaints, and preoperative neurological findings were examined. The Enneking classification system was used for staging, and the Spinal Instability Neoplastic Score was used for spinal instability assessment. **Results:** There were six males and three females (16–54 years of age, mean age: 31.2) among the patients with osteoid osteoma and six males and three females (5–32 years of age, mean age: 17.9) among the patients with osteoblastoma. In all patients with osteoid osteoma, the Enneking stage was I, and gross total resection was performed. One patient was potentially unstable, and stabilization was performed after resection. Among patients with osteoblastoma, there were 44.4% at Enneking stage II and 55.6% at Enneking stage III. One patient was potentially unstable, and stabilization was performed after resection. Gross total resection was performed in 77.8% of the osteoblastoma cases. Recurrence was observed in 22.2% of the cases. Recurrences were Enneking stage III in cervical localization and patients underwent subtotal resection. **Conclusion:** Recurrences and the need for reoperation were more frequent in Enneking stage III osteoblastomas and in cases in which the patient underwent subtotal resection, particularly in patients with cervical spine tumors.

The Editorial Board declares that the manuscript met the ICMJE "uniform requirements" for biomedical papers.

Redakční rada potvrzuje, že rukopis práce splnil ICMJE kritéria pro publikace zasílané do biomedicínských časopisů.

M. U. Etli¹, R. C. Köylü²,
H. Sarikaya¹, C. K. Yaltırık¹,
C. Sarikaya³, L. Şerifoğlu¹,
A. F. Ramazanoğlu¹, S. Naderi⁴

¹ Department of Neurosurgery, Ümraniye Training and Research Hospital, Istanbul, Turkey

² Department of Neurosurgery, Sancaktepe Şehit Prof.Dr. İlhan Varank Training and Research Hospital, İstanbul, Turkey

³ Department of Neurosurgery, Sivas State Hospital, Sivas, Turkey

⁴ Department of Neurosurgery, İstanbul Brain and Spine Center, İstanbul, Turkey



Mustafa Umut Etli, MD
Department of Neurosurgery
Umraniye Training and Research Hospital
Umraniye Eğitim ve Araştırma Hst.
34764 Umraniye/Istanbul
Turkey
e-mail: umutetli@gmail.com

Accepted for review: 22. 1. 2024

Accepted for print: 25. 7. 2024

Key words

spine tumor – osteoid osteoma – osteoblastoma – spinal instability neoplastic score – Enneking

Klíčová slova

nádor páteře – osteoidní osteom – osteoblastom – neoplastické skóre nestability páteře (SINS) – Ennekingova klasifikace

Souhrn

Východiska: Osteom a osteoidní osteom jsou klasifikovány jako benigní podtypy osteogenních nádorů páteře a osteoblastom je klasifikován jako intermediární podtyp. Cílem této studie bylo představit náš chirurgický přístup k pacientům s těmito nádory a poskytnout informace o vztahu mezi chirurgickou léčbou a recidivou. **Metody:** Retrospektivně bylo hodnoceno 18 pacientů, kteří podstoupili operaci na naší klinice. Byly zkoumány demografické charakteristiky, obtíže v době prezentace onemocnění a předoperační neurologické nálezy. Pro staging byl použit Ennekingův klasifikační systém a pro hodnocení nestability páteře bylo použito Skóre neoplastické nestability páteře (Spinal Instability Neoplastic Score; SINS). **Výsledky:** Mezi pacienty s osteoidním osteomem bylo šest mužů a tři ženy (ve věku 16–54 let, průměrný věk 31,2 let) a mezi pacienty s osteoblastomem šest mužů a tři ženy (ve věku 5–32 let, průměrný věk 17,9 let). Všichni pacienti s osteoidním osteomem měli podle Ennekingovy klasifikace stadium I a byla u nich provedena rozsáhlá totální resekce. Jeden pacient byl potenciálně nestabilní a po resekci u něj byla provedena stabilizace. Mezi pacienty s osteoblastomem mělo 44,4 % onemocnění ve stadiu II a 55,6 % ve stadiu III podle Ennekingovy klasifikace. Jeden pacient byl potenciálně nestabilní a po resekci u něj byla provedena stabilizace. V 77,8 % případů osteoblastomu byla provedena rozsáhlá totální resekce. Recidiva byla pozorována u 22,2 % případů. Podle Ennekingovy klasifikace byly recidivy lokalizované v krční páteři ve stadiu III a pacienti podstoupili subtotální resekci. **Závěr:** Recidivy a nutnost reoperace byly častější u osteoblastomů stadia III podle Ennekingovy klasifikace a v případech, kdy pacient podstoupil subtotální resekci, zejména u pacientů s nádory krční páteře.

Introduction

While osteoid osteomas (OO) and osteoblastomas (OB) were previously considered to be the same entities due to their similar histological appearances, they were later treated as different diseases in the literature due to their different radiological and clinical features [1]. OOs and OBs are defined as osteogenic spine tumors. The benign and intermediate osteogenic tumors of the spine that have not been changed in the update of the World Health Organization 2020 classification are osteomas, OOs, and OBs [2]. While OOs and osteomas are classified as a subtype of benign osteogenic spinal tumors, OB is classified as intermediate.

Osteoid osteoma was first described by Bergstrand in 1930. It was later reported by Jaffe in 1935 as a benign bone tumor in the form of vascular osteoid tissue surrounded by a dense sclerotic bone margin [3]. OBs, on the other hand, were defined by Jaffe and Lichtenstein in 1956 as vascular osteoid and bone-shaped tumors that contain many osteoblasts, are benign in appearance and occur mainly in the vertebral column [4,5]. While OOs and OBs, which are rare tumors, are observed in 3% and 1% of all primary bone tumors, respectively, their rates of incidence in the vertebral column are 20% and 40%, respectively [6–9].

Osteoid osteomas are usually smaller than 1 cm and are self-limiting, while OBs are larger than 1 cm, can be seen expanding into the canal, and rarely become malignant [10]. Radiographically, both lesions appear as mixed density and are usually surrounded by a well-circumscribed sclerotic periphery. OOs generally show a larger area of sclerotic bone formation than OBs, whereas OBs are known to enlarge and erode the surrounding bone [11,12].

In the literature, many studies classify different aspects of these tumors, including staging, anatomical relationships, and effects on stability [13,14].

The aim of this study was to present our surgical approach to osteogenic spine tumors by examining them in light of classifications and to provide information about the relationship between surgical treatment and recurrence.

Materials and methods

Six hundred and one patients operated on for spinal tumors in Umraniye Training and Research Hospital Neurosurgery Department between 2010 and 2020 were retrospectively analyzed from patient charts. Five hundred and eighty-three patients whose histopathological diagnosis was not OO or OB were excluded from the study. Nine patients who underwent surgery for OO and nine who underwent surgery for OB between 2014 and 2020 were retrospectively evaluated.

Our study examined the patients' demographic characteristics, presentation complaints, and preoperative neurological findings. In addition, the patients' CT and MRI were evaluated preoperatively. Patients with suspected spinal tumors in their preoperative radiological imaging were operated on for tumor resection and histopathological diagnosis. The Enneking classification system was used for staging [15].

The Enneking classification indicates the aggressiveness level of the tumor and consists of three components: Stage I, II, and III tumors [13,15].

- Stage I – latent or inactive tumor surrounded by a well-circumscribed capsule; grows very slowly.

- Stage II – active tumor surrounded by a thin capsule and a reactive tissue layer; grows slowly.
- Stage III – aggressive tumor surrounded by a very thin incomplete or absent capsule; a wide reactive hypervascular pseudo-capsule invades neighboring tissue; grows very rapidly; associated with high recurrence rate; histological features include large epithelioid osteoblasts either rimming the osteoid or forming a clustered matrix.

The Spinal Instability Neoplastic Score (SINS) was used for the spinal instability assessment [16]. Patients who had no spinal instability (SINS < 7) underwent tumor resection and decompression surgery, and patients who had spinal instability (SINS ≥ 7) underwent decompression and stabilization procedures. The same senior surgeon performed all the surgeries.

The amount of resection was evaluated in terms of subtotal or total resection with contrast-enhanced MRI performed within the first 48 h. Neurological examinations and additional complaints noted before discharge in the postoperative period were included in the study.

Patients were followed for 24–125 months (mean 51.7 months) in the late postoperative period, and additional complaints and neurological examinations recorded during follow-up were included in the study. The patients were evaluated for recurrence with contrast-enhanced MRI during the follow-up period.

Results

The pathologies of the patients included in the study were reported as nine OOs and nine OBs (Tab. 1).

Tab. 1. Tumor pathologies and locations, demographic characteristics, presence of tumor resection, presence of recurrence, type of surgery, Spinal Instability Neoplastic Scores, and Enneking stages of the patients.

	Pathology	Location	Age	Sex	Resection	Recurrence	Surgery	SINS	Enneking
1	OO	L1	26	male	GTR	no	R	4	1
2	OO	T10-11	16	male	GTR	no	R	5	1
3	OO	L5	28	female	GTR	no	R	5	1
4	OO	sacrum	47	female	GTR	no	R	4	1
5	OO	C4	22	male	GTR	no	R + F	7	1
6	OO	T5-7	23	female	GTR	no	R	3	1
7	OO	T3	44	male	GTR	no	R	3	1
8	OO	L4	21	male	GTR	no	R	6	1
9	OO	sacrum	54	male	GTR	no	R	5	1
10	OB	L1	14	female	GTR	no	R	4	2
11	OB	C5	7	female	STR	yes	R	6	3
12	OB	C2	21	male	STR	yes	R	6	3
13	OB	T9-10	32	female	GTR	no	R	3	3
14	OB	T8	28	male	GTR	no	R	3	2
15	OB	L5-S1	14	male	GTR	no	R	5	2
16	OB	L5	25	male	GTR	no	R	6	2
17	OB	T1	15	male	GTR	no	R	5	3
18	OB	C5	5	male	GTR	no	R+F	8	3

F – fusion; GTR – gross total resection; OB – osteblastoma; OO – osteoid osteoma; R – resection; STR – subtotal resection

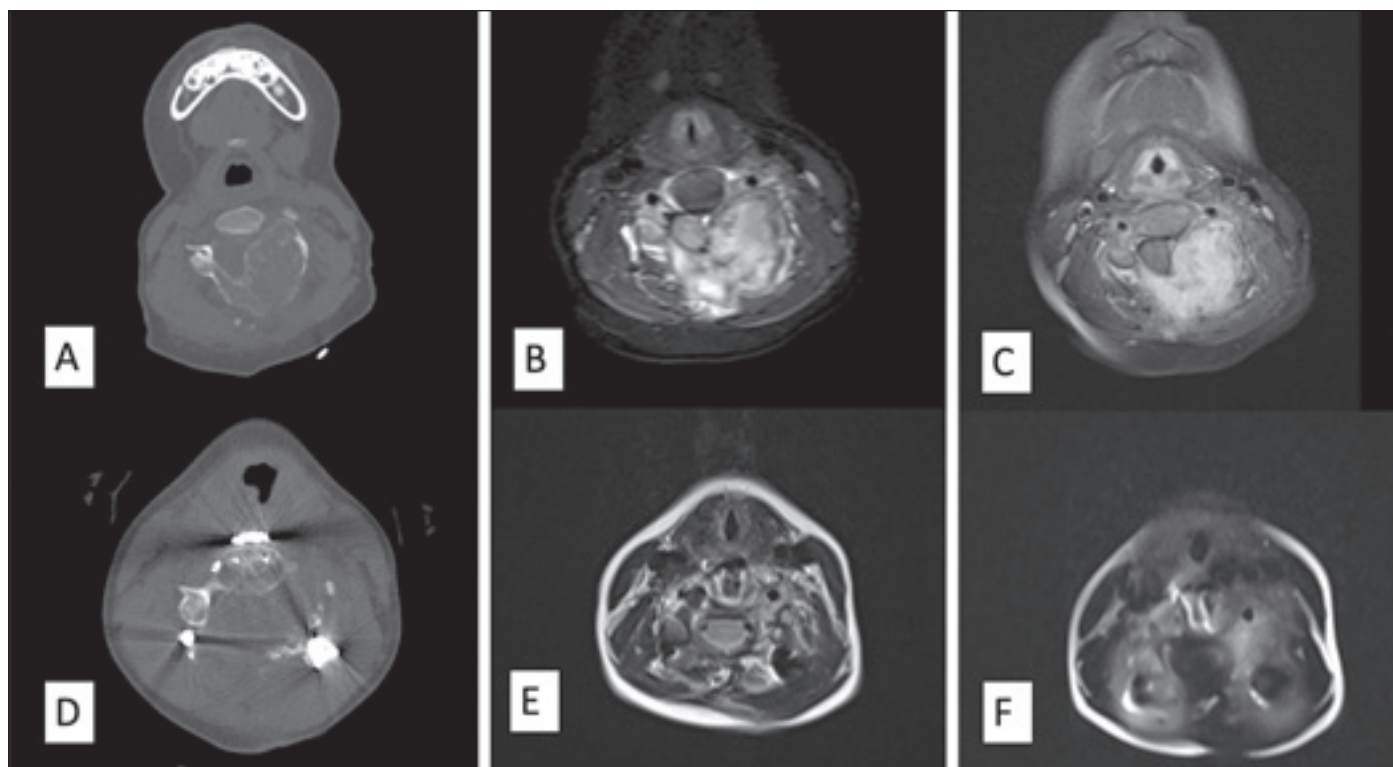


Fig. 1. Images of the osteblastoma patient who underwent instrumentation (Patient 18): (A) preoperative axial CT image; (B) preoperative axial T2-weighted MRI image; (C) preoperative axial postcontrast T1-weighted MRI image; (D) postoperative axial CT image; (E) postoperative axial T2-weighted MRI image; (F) postoperative axial postcontrast T1-weighted MRI image.

Obr. 1. Snímky pacienta s osteblastomem, který podstoupil instrumentaci (pacient 18). (A) předoperační axiální obraz CT; (B) předoperační axiální T2-vážený obraz MR; (C) předoperační axiální postkontrastní T1-vážený obraz MR; (D) pooperační axiální obraz CT; (E) pooperační axiální T2-vážený obraz MR; (F) pooperační axiální postkontrastní T1-vážený obraz MR.

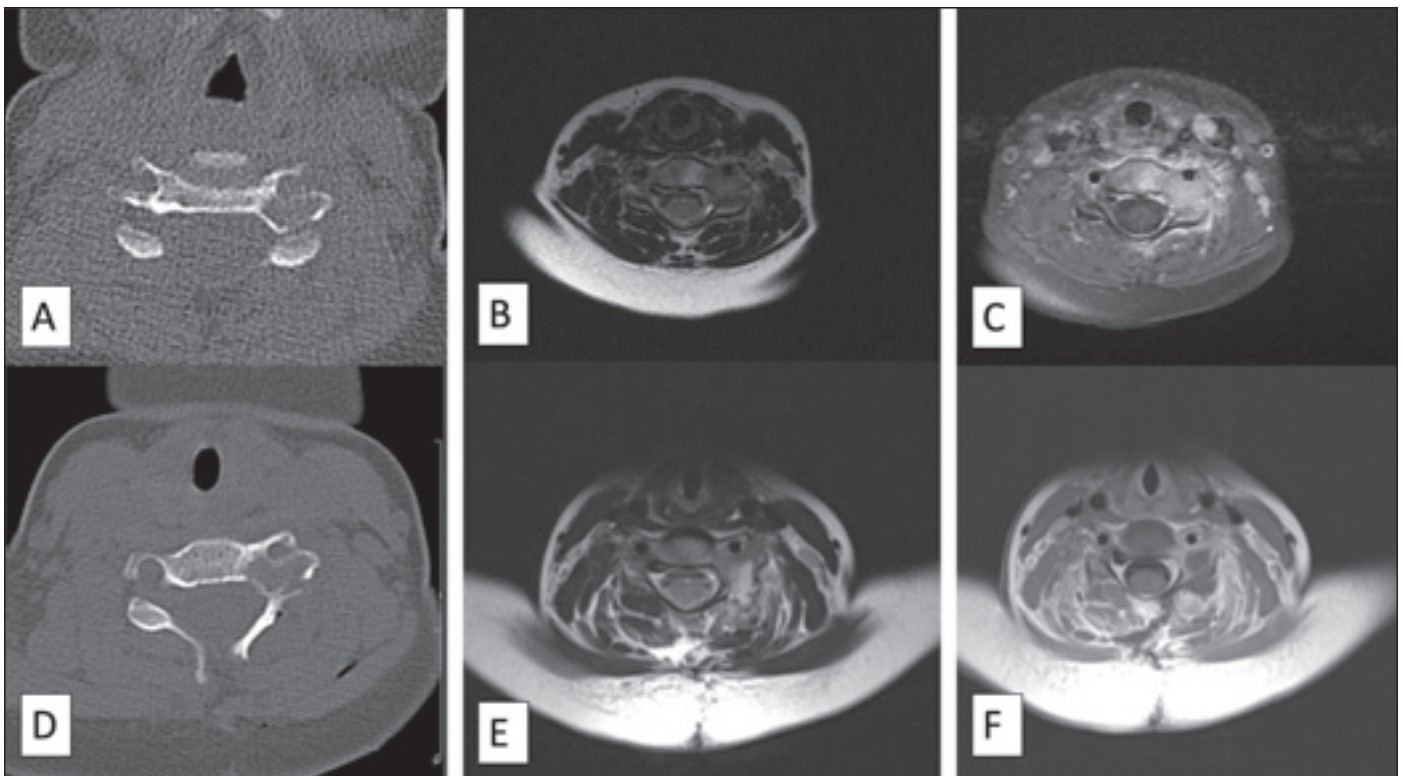


Fig. 2. Images of the patient with recurrent osteoblastoma (Patient 11) before recurrence: (A) preoperative axial CT image; (B) preoperative axial T2-weighted MRI image; (C) preoperative axial postcontrast T1-weighted MRI image; (D) postoperative axial CT image; (E) postoperative axial T2-weighted MRI image; (F) postoperative axial postcontrast T1-weighted MRI image.

Obr. 2. Snímky pacientky s rekurentním osteoblastomem (pacientka 11) před rekurencí: (A) předoperační axiální obraz CT; (B) předoperační axiální T2-vážený obraz MR; (C) předoperační axiální postkontrastní T1-vážený obraz MR; (D) pooperační axiální obraz CT; (E) pooperační axiální T2-vážený obraz MR; (F) pooperační axiální postkontrastní T1-vážený obraz MR.

Osteoid osteoma

The patient population consisted of six males and three females, with a mean age of 31.2 years (range: 16–54 years).

The primary presenting complaint was axial pain associated with the localization of the tumor in seven (77.8%) patients and radicular pain in two (22.2%) patients. Cervical localization was observed in one (11.1%) patient, thoracic in three (33.3%), lumbar in three (33.3%), and sacral localization in two (22.2%) patients. The Enneking stage was found to be I in all OO cases (100%).

The SINS score was found to be seven in one case and less than seven in eight cases. Gross total resection was performed in all (100%) of the patients. In the patient with a SINS score of seven, a stabilization procedure was performed after resection. No neurological deficit was observed after surgery in the short or long term.

Osteoblastoma

The patient population consisted of six males and three females, with a mean age of 17.9 years (range: 5–32 years).

The primary presenting symptom was axial pain associated with the localization of the tumor in six (66.7%) patients and radicular pain in three (33.3%) patients. Neurological deficits were not observed in any of the patients. Cervical localization was observed in three (33.3%) cases, thoracic in three (33.3%), lumbar in two (22.2%), and lumbosacral localization in one (11.1%) case.

The Enneking stages were found to be stage II in four patients (44.4%) and stage III in five patients (55.6%). The SINS score was found to be eight in one patient and less than seven in eight patients.

Gross total resection was performed in seven (77.8%) patients, and subtotal resection was performed in two (22.2%) patients. Eight patients were operated on only for tumor resection, while fusion was performed after resection in one (11.1%) patient with a SINS score of 8 (Fig. 1).

No neurological deficits were observed during the postoperative period. Recurrence was observed in two patients (22.2%) (Patient 11 and 12) with Enneking stage III cervical spine OB who underwent subtotal resec-

tion. Both cases underwent revision surgery for radical decompression and instrumentation surgery. Patient 11, a pediatric case, exhibited a small residual lesion following the initial surgery. The family initially declined further surgical intervention. Two years later, the onset of acute C5 motor lesion necessitated a comprehensive revision surgery involving both anterior and posterior approaches. (Fig. 2–3). Patient 12, who presented with recurrent disease, had previously undergone surgical intervention at another facility. Given the extensive tumor invasion observed, a combined anterior and posterior approach at the craniovertebral junction was executed. Despite these comprehensive efforts, certain tumor remnants remained inaccessible. However, a new recurrence and transformation to osteosarcoma was observed, and this patient died because of multiple metastases.

Discussion

Osteoid osteomas and OBs demonstrate different characteristics and behaviors. OBs were diagnosed in younger patients (mean age 17.9) when compared to OOs (mean age

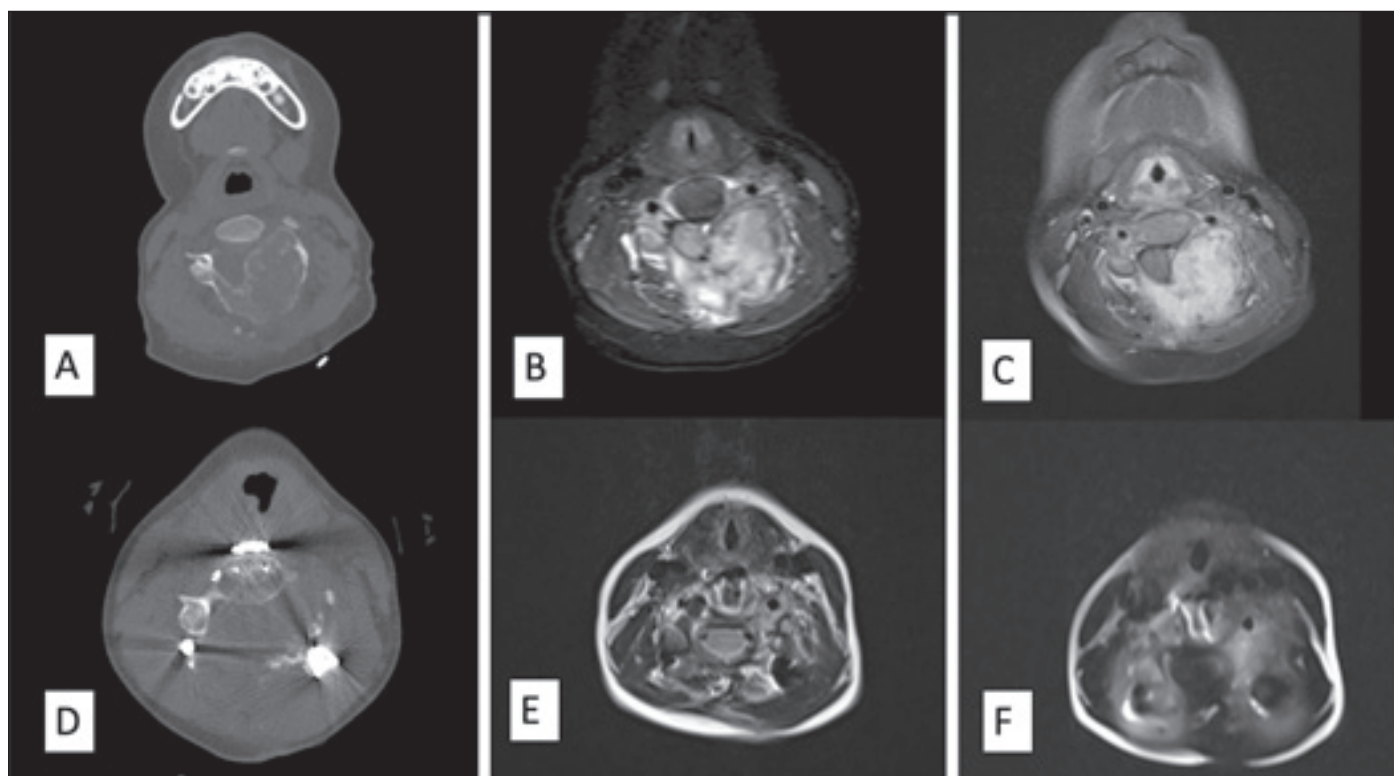


Fig. 3. Images of the patient with recurrent osteoblastoma (Patient 11) after recurrence: (A) axial CT image; (B) axial T2-weighted MRI image; (C) axial postcontrast T1-weighted MRI image; (D) postoperative axial CT image; (E) postoperative axial T2-weighted MRI image; (F) postoperative axial postcontrast T1-weighted MRI image.

Obr. 3. Snímky pacientky s rekurentním osteoblastomem (pacientky 11) po rekurenci: (A) axiální obraz CT; (B) axiální T2-vážený obraz MR; (C) axiální postkontrastní T1-vážený obraz MR; (D) pooperační axiální obraz CT; (E) pooperační axiální T2-vážený obraz MR; (F) pooperační axiální postkontrastní T1-vážený obraz MR.

31.2) in the current study. The study also revealed that OOs are not aggressive tumors and are commonly Enneking stage 1, while OBs are commonly Enneking stage II and III. Furthermore, when comparing SINS scores, both tumors may cause primary or iatrogenic spinal instability. However, the risk of primary and iatrogenic instability is more common in OBs.

The Enneking classification system has been widely used for the staging of spinal tumors. Each stage represents the level of aggressiveness in osteogenic tumors. Therefore, knowing the stage of the tumor before surgery is important.

Since almost all cases of OO are accepted as Enneking Stage I, there is no detailed publication on the Enneking staging of OOs. However, there are many reports on the staging of OBs based on the Enneking classification. Previous publications have reported different rates of stages II and III in OBs.

In some studies, OBs have been classified as stage II in 72–80% of cases and as stage III in 20–28% of patients [14,17,18], while in other studies, stage II was reported

as 20–25%, and stage III was reported as 75–80% [13,19]. In our OB series, four cases (44.4%) were stage II, and five (55.6%) were stage III.

Although OBs are considered benign or intermediate bone tumors, they can progress more aggressively and show malignant transformation or cause local recurrence [9,20–22]. Therefore, most research recommends intralesional gross total resection for Enneking stage II lesions and en bloc resection when “anatomically appropriate” for Enneking stage III lesions [13,14,18].

Recurrence rates of 10–24% for stage II tumors and up to 50% for stage III OBs have been reported [13,19–21,23]. Recurrence was observed in 2 (22.2%) of our patients who had stage III osteoblastoma. In other words, while there was no recurrence in our stage II OBs, the rate of recurrence in the stage III OBs was 40%.

An essential factor to consider when planning resections for all spinal tumors is the risk of iatrogenic instability. Although SINS scoring has been defined primarily for metastatic disease, there are examples of it being

used in different spinal tumors [24–27]. Elder et al. used SINS for the first time in OB [14]. In their study, they applied fusion to all patients with a SINS score of six or greater. In our study, 11.1% of the OO patients and 11.1% of the OB patients had SINS scores greater than six. In these patients, total resection and fusion were performed, and no recurrence was observed in the postoperative period. Our study also demonstrated that aggressive resection of tumors dictates stabilization and fusion. The risk of instability was much higher in pediatric cases with cervical spine tumors.

This study is the first to use the Enneking and SINS classifications together in benign and intermediate osteogenic spinal tumors (OO and OB).

Our study shows that recurrence and the need for reoperation are more frequent in patients with a high Enneking stage and subtotal resection, especially in the cervical region. However, the SINS score should be considered in these patients to evaluate instability. This is in agreement with previous studies [14]. The most important limitation of our study was the small number of

patients, but the diseases examined in the study are rare by nature. However, to apply a standard treatment protocol, the study included patients who were operated on by the same primary surgeon in the same operating room with the same equipment.

Recurrence and the need for reoperation are more frequent in patients with Enneking stage III OBs and in patients who underwent subtotal resection, particularly in patients with cervical spine tumors. In the case of Enneking stage III tumors, radical surgery is the preferred treatment modality. However, patient preferences, familial decisions, characteristics of tumors, or prior surgical interventions may impose constraints on the choice of surgical approach. The SINS scoring system may help in the assessment of instability in these cases.

Ethical aspects

The entire study was conducted in accordance with the Helsinki Declaration of 1975 (as revised in 2004 and 2008). Ethical approval for the study was obtained from Umraniye Training and Research Hospital Committee with the B.10.1.TKH.4.34.H.GP.0.01/351 ID number (date of approval: 26. 8. 2021). Before the study was conducted, an informed consent was obtained from patients for their inclusion in the study.

Conflicts of interest

The authors declare they have no potential conflicts of interest concerning drugs, products, or services used in the study.

References

1. Azouz EM, Kozłowski K, Marton D et al. Osteoid osteoma and osteoblastoma of the spine in children. *Pediatr Radiol* 1986; 16(1): 25–31. doi: 10.1007/BF02387501.
2. Tosun I, Naderi S. Approach to primary vertebral tumors in the light of the 2020 updated World Health Organization Classification of bone tumors. *Turk Neurosurg* 2023; 33(1): 1–9. doi: 10.5137/1019-5149.JTN.36208-21.2.
3. Jaffe HL. Osteoid-osteoma: a benign osteoblastic tumor composed of osteoid and atypical bone. *Archives of Surgery* 1935; 31(5): 709–728. doi: 10.1001/archsurg.1935.01180170034003.
4. Jaffe HL. Benign osteoblastoma. *Bull Hosp Joint Dis* 1956; 17(2): 141–151.
5. Lichtenstein L. Benign osteoblastoma. A category of osteoid- and bone-forming tumors other than classical osteoid osteoma, which may be mistaken for giant-cell tumor or osteogenic sarcoma. *Cancer* 1956; 9(5): 1044–1052. doi: 10.1002/1097-0142(195609/10)9:5<1044::aid-cnrcr2820090523>3.0.co;2-o.
6. Frassica FJ, Waltrip RL, Sponseller PD et al. Clinicopathologic features and treatment of osteoid osteoma and osteoblastoma in children and adolescents. *Orthop Clin North Am* 1996; 27(3): 559–574.
7. Healey JH, Ghelman B. Osteoid osteoma and osteoblastoma. Current concepts and recent advances. *Clin Orthop Relat Res* 1986; 204: 76–85.
8. Jackson RP, Reckling FW, Mants FA. Osteoid osteoma and osteoblastoma. Similar histologic lesions with different natural histories. *Clin Orthop Relat Res* 1977; 128: 303–313.
9. Marsh BW, Bonfiglio M, Brady LP et al. Benign osteoblastoma: range of manifestations. *J Bone Joint Surg Am* 1975; 57(1): 1–9.
10. Janin Y, Epstein J, Carras R et al. Osteoid osteomas and osteoblastomas of the spine. *Neurosurgery* 1981; 8(1): 31–38. doi: 10.1227/00006123-198101000-00007.
11. Atesok KI, Alman BA, Schemitsch EH et al. Osteoid osteoma and osteoblastoma. *J Am Acad Orthop Surg* 2011; 19(11): 678–689. doi: 10.5435/00124635-201111000-00004.
12. Nielsen GP, Rosenberg AE. Update on bone forming tumors of the head and neck. *Head Neck Pathol* 2007; 1(1): 87–93. doi: 10.1007/s12105-007-0023-4.
13. Versteeg AL, Dea N, Boriani S et al. Surgical management of spinal osteoblastomas. *J Neurosurg Spine* 2017; 27(3): 321–327. doi: 10.3171/2017.1.SPINE16788.
14. Elder BD, Goodwin CR, Kosztowski TA et al. Surgical management of osteoblastoma of the spine. Case series and review of the literature. *Turk Neurosurg* 2016; 26(4): 601–607. doi: 10.5137/1019-5149.JTN.14348-15.1.
15. Enneking WF. A system of staging musculoskeletal neoplasms. *Instr Course Lect* 1988; 37: 3–10.
16. Fisher CG, DiPaola CP, Ryken TC et al. A novel classification system for spinal instability in neoplastic disease: an evidence-based approach and expert consensus from the Spine Oncology Study Group. *Spine (Phila Pa 1976)* 2010; 35(22): E1221–E1229. doi: 10.1097/BRS.0b013e3181e16ae2.
17. Denaro V, Denaro L, Papalia R et al. Surgical management of cervical spine osteoblastomas. *Clin Orthop Relat Res* 2007; 455: 190–195. doi: 10.1097/01.blo.0000238846.34047.d9.
18. Ruggieri P, Huch K, Mavrogenis AF et al. Osteoblastoma of the sacrum: report of 18 cases and analysis of the literature. *Spine (Phila Pa 1976)* 2014; 39(2): E97–E103. doi: 10.1097/BRS.0000000000000061.
19. Boriani S, Amendola L, Bandiera S et al. Staging and treatment of osteoblastoma in the mobile spine: a review of 51 cases. *Eur Spine J* 2012; 21(10): 2003–2010. doi: 10.1007/s00586-012-2395-8.
20. Berry M, Mankin H, Gebhardt M et al. Osteoblastoma: a 30-year study of 99 cases. *J Surg Oncol* 2008; 98(3): 179–183. doi: 10.1002/jso.21105.
21. Lucas DR, Unni KK, McLeod RA et al. Osteoblastoma: clinicopathologic study of 306 cases. *Hum Pathol* 1994; 25(2): 117–134. doi: 10.1016/0046-8177(94)90267-4.
22. Dorfman HD, Weiss SW. Borderline osteoblastic tumors: problems in the differential diagnosis of aggressive osteoblastoma and low-grade osteosarcoma. *Semin Diagn Pathol* 1984; 1(3): 215–234.
23. Harrop JS, Schmidt MH, Boriani S et al. Aggressive “benign” primary spine neoplasms: osteoblastoma, aneurysmal bone cyst, and giant cell tumor. *Spine (Phila Pa 1976)* 2009; 34 (22 Suppl): S39–S47. doi: 10.1097/BRS.0b013e3181ba0024.
24. Zadnik PL, Goodwin CR, Karami KJ et al. Outcomes following surgical intervention for impending and gross instability caused by multiple myeloma in the spinal column. *J Neurosurg Spine* 2015; 22(3): 301–309. doi: 10.3171/2014.9.SPINE14554.
25. Ramazanoglu AF, Aydin SO, Etli MU et al. Role of spinal instability neoplastic score in management of spinal plasmacytoma. *World Neurosurg* 2022; 161: e303–e307. doi: 10.1016/j.wneu.2022.02.008.
26. Baumgart L, Barz M, Delbridge C et al. Spinal lesions as clinical manifestations of plasma cell neoplasia. *Curr Oncol* 2022; 29(9): 6236–6244. doi: 10.3390/curroncol29090490.
27. Ramazanoglu AF, Etli MU, Sarikaya C et al. Management of spinal lymphomas: spinal instability assessment using the Spinal Instability Neoplastic Score and a proposed treatment algorithm. *Turk Neurosurg* 2022; 32(4): 649–656. doi: 10.5137/1019-5149.JTN.35770-21.2.

Impakt faktor časopisu Česká a slovenská neurologie a neurochirurgie pro rok 2023 činí **0,3**.