

doi: 10.48095/ccsnn2021570

Depiction of cerebrospinal fluid flow with a single sequence – variable flip angle turbo spin echo

Zobrazení průtoku mozkomíšního moku jednou sekvencí – variable flip angle turbo spin echo

Dear Editors,

Variable flip angle turbo spin echo (VFA-TSE) sequences play an important role in the evaluation of cystic lesions and cerebrospinal fluid (CSF) spaces. In current MRI protocols, most conventional T2-weighted turbo spin echo (TSE-T2W) sequences are obtained with flow compensation. Flow-compensated TSE-T2W sequences prevent parenchymal artifacts caused by CSF flow, but this also results in a decrease in or loss of the CSF flow signal void. VFA-TSE sequences provide additional flow information by highlighting the signal void of the flow. The use of such sequences can contribute to the radiological differential diagnosis, especially when it is necessary to understand the relationship between lesions and CSF spaces. The use of the variant flip angle is available in different sequences under different brands of imaging devices (e.g., T2W SPACE, GE/T2W CUBE [Siemens, Munich, Germany], and VISTA [Philips, Amsterdam, Netherlands]) [1].

A 41-year-old male patient presented to the neurology outpatient clinic with the complaint of a persistent headache. The neurological examination findings were normal except for papilledema. The brain MRI revealed a large cystic lesion in the left middle cranial fossa extending to superior frontal planes. The lesion was isointense with CSF in all sequences and showed no sign of restricted diffusion. In the described lesion, a sign of CSF flow extending from the medial wall of the lesion into the lesion was detected in the VFA-TSE sequence (Fig. 1A). The lesion was evaluated to be consistent with a communicating arachnoid cyst associated with the suprasellar cistern.

A 49-year-old patient, who was operated on due to a Chiari 1 malformation, underwent brain MRI due to persistent cephalgia after the operation. In the brain MRI, a limited fluid collection that was isointense with CSF was observed at the level of the suboccipital defect secondary to the operation. The VFA-TSE sequence revealed a hypointense line of fluid collection associated with CSF flow, extending into the anterior wall. CSF flow was marked in the VFA-TSE sequence, which indicated a dural defect in the anterior wall (Fig. 1B), and the lesion was evaluated to be consistent with a pseudomeningocele secondary to the operation. Taydas et al previously showed that the VFA-TSE sequence was a successful method in the diagnosis of pseudomeningocele as a postoperative complication [2].

A 35-year-old male patient presented to our hospital with a complaint of weakness in the right arm that had started one month after trauma. In cervical MRI, a 14 × 8 mm cystic lesion that was isointense with CSF was observed in all sequences in the right neural foramen at the level of the C5-6 intervertebral disc. In the differential diagnosis of the described pure cystic lesion, perineural cyst and pseudomeningocele were considered. The VFA-TSE sequence obtained showed a hypointense flow void line of CSF flow between the subarachnoid space and the cystic lesion (Fig. 1C). The finding was evaluated to be consistent with a dural tear and pseudomeningocele secondary to trauma.

Brain MRI was performed in a 21-year-old male patient who was being followed up for hydrocephalus. In further examinations, including the VFA-TSE sequence in addition to conventional sequences in brain MRI, steno-

The Editorial Board declares that the manuscript met the ICMJE "uniform requirements" for biomedical papers.

Redakční rada potvrzuje, že rukopis práce splnil ICMJE kritéria pro publikace zasílané do biomedicínských časopisů.

A. N. Şirin Özcan

Department of Radiology, Ankara Bilkent City Hospital, Ankara, Turkey



Ayşe Nur Şirin Özcan

Department of Radiology
Ankara Bilkent City Hospital
Bilkent/Lodumlu 06800 Ankara
Turkey

e-mail: aysenursirinozcan@gmail.com

Accepted for review: 17. 6. 2021

Accepted for print: 3. 11. 2021

sis was detected at the level of the cerebral aqueduct. In addition, a significant CSF flow void was detected in the VFA-TSE sequence at the base of the third ventricle of the patient who had no history of surgery. The CSF flow between the third ventricle and the prepontine cistern was evaluated as a spontaneous third ventriculostomy (Fig. 1D). As reported previously, the VFA-TSE sequence provides useful information in the evaluation of the third ventriculostomy when obtained alone or in addition to high-resolution 3D heavily T2W sequences [3].

The VFA-TSE sequence, which is available under different brands and commercial names, provides additional information in the evaluation of the relationship between

cystic lesions and CSF spaces and the relationship between different CSF spaces [4]. In the literature, high-resolution 3D heavily T2W sequences with the balanced steady-state free precession feature (e.g., CISS [Siemens, Munich, Germany], FIESTA [General Electric, Schenectady, NY, USA], and B-FFA [Philips, Amsterdam, Netherlands]) have been defined for this purpose. However, these sequences show the cystic lesion or meningeal defect, but not the flow, and in order to visualize the flow, additional phase-contrast MRI sequences should be used. The VFA-TSE sequences with variable longer echo times substantially increase the flow void in the image. Also, because of the 3D acquisition feature, VFA-T2W sequence allows the use of thin slices (usually 1 mm or similar), it thus offers better space resolution than the standard TSE-T2W (average slice thickness 3–6 mm). It also assists in visualizing small structures, such as the cyst wall.

In conclusion, VFA-TSE sequence successfully shows defects in cystic lesions or the meninges and allows the evaluation of CSF flow based on a single sequence.

References

1. Mugler JP III, Altes TA, Horger W et al. Improved T2-weighted Imaging of the Pelvis using T2-prepared Single-slab 3D TSE (SPACE). *Proc Intl Soc Mag Reson Med* 2011; 107(50): 21707–21712.
2. Taydas O, Ogul H, Gozgec E et al. Evaluation of craniocervical pseudomeningoceles with three-dimensional T2-SPACE sequence at 3T. *Acta Radiol* 2021; 62(1): 80–86. doi: 10.1177/0284185120912507.
3. Algin O, Ucar M, Ozmen E et al. Assessment of third ventriculostomy patency with the 3D-SPACE technique: a preliminary multicenter research study. *J Neurosurg* 2015; 122(6): 1347–1355. doi: 10.3171/2014.10.JNS14298.
4. Algin O. Evaluation of hydrocephalus patients with 3D-SPACE technique using variant FA mode at 3T. *Acta Neurol Belg* 2018; 118(2): 169–178. doi: 10.1007/s13760-017-0838-z.

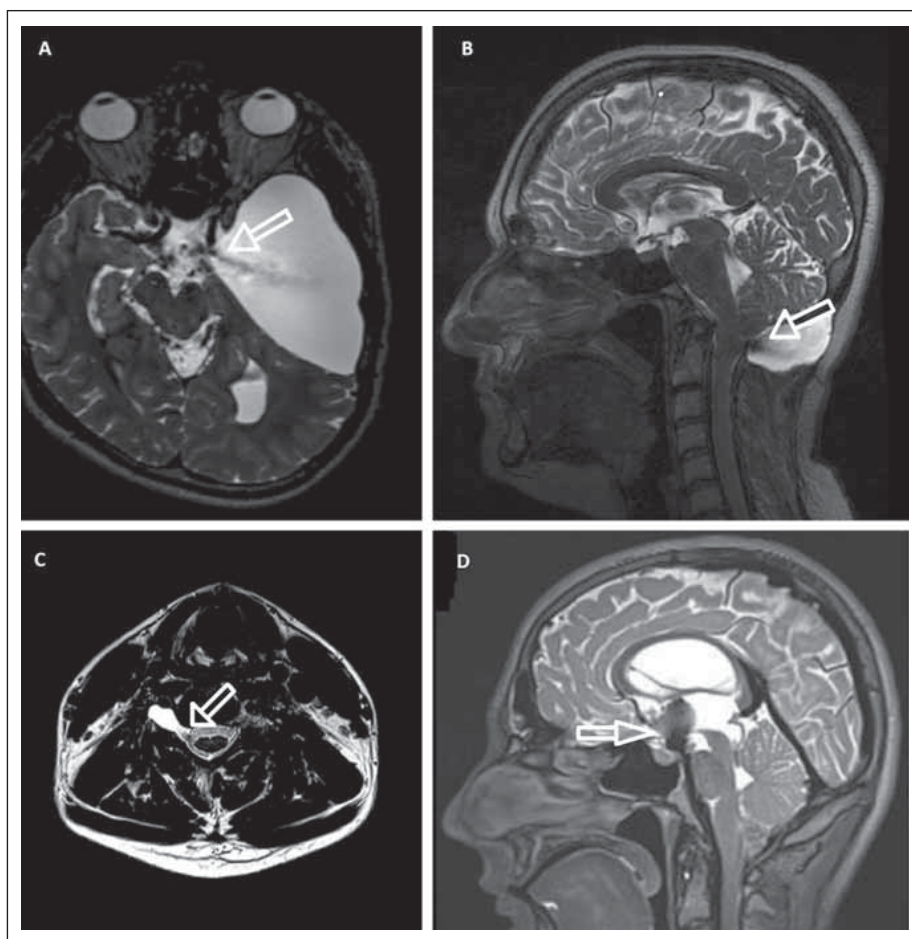


Fig. 1. VFA-TSE images of different cases showing (A) the communication between a large arachnoid cyst and CSF flow signal void inside the cyst, (B) CSF flow signal void inside a pseudomeningocele, (C) CSF flow signal void between the pseudomeningocele and subarachnoid space due to a dural tear, and (D) significant CSF flow signal void between the third ventricle and the prepontine cistern caused by a spontaneous third ventriculostomy
CSF – cerebrospinal fluid; VFA-TSE – variable flip angle turbo spin echo

Obr. 1. Snímky z VFA-TSE různých případů ukazují (A) komunikaci mezi velkou arachnoidální cystou a prázdným signálem průtoku CSF v cystě, (B) prázdný signál průtoku likvoru v pseudomeningokéle, (C) prázdný signál průtoku likvoru mezi pseudomeningokélou a subarachnoidálním prostorem v důsledku trhliny v durálním vaku, a (D) významný prázdný signál průtoku CSF mezi třetí mozkovou komorou a prepontinní cisternou v důsledku spontánní ventrikulostomie třetí mozkové komory

VFA-TSE – variable flip angle turbo spin echo

Impakt faktor časopisu Česká a slovenská neurologie a neurochirurgie pro rok 2020 činí **0,35**.