

Thrombosis of the supraorbital ophthalmic vein

Trombóza horní orbitální žíly

Dear editor,

With an incidence of 3–4/1,000,000 persons per year, superior ophthalmic vein thrombosis (SOVT) is a rare and serious pathological process of the orbit [1]. Its primary clinical manifestation is sudden and painful exophthalmos in addition to chemosis and conjunctival congestion [2,3]. SOVT can also be a secondary symptom of septic and aseptic conditions, e.g., orbital cellulitis in paranasal sinusitis [1,2], septic thrombosis of the cavernous sinus, vascular malformations, Tolosa-Hunt syndrome, or tumours of the orbit and cavernous sinus [3]. Imaging methods are principally used for the diagnosis.

The possible systemic risk factors are hypercoagulant conditions, inflammation, and systemic malignancies [1,2,4].

Thrombosis of the supraorbital vein in connection with varices of the orbit is even rarer than SOVT – we could only find eight described cases so far. The aetiology is not clear; primary varices are congenital and typically manifested during the second and third decades of life whereas the secondary often result from retrograde filling in vascular malformations, e.g., carotid cavernous fistula or intracranial arteriovenous malformation [5,6].

A 36-year-old woman was referred to our department with a history of a day-long painful swelling of the right upper eyelid with exophthalmos. The patient also described an intermittent feeling of “my eyes popping out of my head” during the Vals-

alva manoeuvre, laughter, or trunk bending. A more detailed interview revealed the suppression of olfactory and gustatory perception during the Valsalva manoeuvre, which had been long investigated and monitored in the neurological outpatient department. This was followed up by a psychiatrist as a converse disorder. She was a non-smoker and the medication received was non-thrombogenic.

A dominant protrusion of the right eye and dilatation of episcleral vessels were revealed. The anterior segment was without pathology. No relative afferent pupillary defect was observed in both eyes. The patient presented with diplopia and moderate pain when looking towards the upper-right quadrant. Right eye protrusion reached 6 mm (Exophthalmometry: 28-105-22) (Fig. 1). The posterior segment showed upper-limit excavation of the optic nerve (0.35 c/d). The best corrected visual acuity (BCVA) was 6/12 in both eyes was found. Intraocular pressure was 25 mmHg in the right eye and 18 mmHg in the left one.

Full-field perimetry revealed a concentric narrowing with a preserved central sector in the range of 10–20 degrees. CT and MRI showed no corresponding CNS correlation. A below normal bilateral reduction of the retinal nerve fibre layer (RNFL) was observed in the temporal quadrant through optical coherence tomography. Further laboratory testing revealed a slight increase in C-Reactive Protein (CRP) (12.65 mg/L). A total blood cell count analysis excluded the possibility of leucocytosis and the patient was afebrile. Other tests, including thyroid gland hormone analysis, were within normal range.

CTA of the head revealed a markedly developed vascular structure in the right orbit pushing the eye ventrally. The brain MRI confirmed thrombosis of a varicose supraorbital vein in the right side; the left section of this varicose vein showed greater development without any blockage (Fig. 2A).

In cooperation with a haematologist, an anticoagulant low-molecular-weight heparin (LMWH) therapeutic strategy was

The Editorial Board declares that the manuscript met the ICMJE “uniform requirements” for biomedical papers.

Redakční rada potvrzuje, že rukopis práce splnil ICMJE kritéria pro publikace zasílané do biomedicínských časopisů.

J. Mikovčíková¹, A. Kopecký^{1,2},
A. Stepanov³, J. Studnička³,
P. Matoušek^{2,4}, P. Komínek^{2,4},
J. Němčanský^{1,2}

¹ Department of Ophthalmology, University Hospital Ostrava

² Department of Craniofacial Disciplines, Faculty of Medicine, University of Ostrava

³ Department of Ophthalmology, Faculty of Medicine Hradec Kralove, Charles University and University Hospital Hradec Kralove

⁴ Department of Otorhinolaryngology and Head and Neck Surgery, University Hospital Ostrava



Jan Němčanský, MD, PhD, MBA
Department of Ophthalmology,
University Hospital Ostrava
17. listopadu 1790/5
708 52 Ostrava-Poruba
Czech Republic
e-mail: jan.nemcansky@fno.cz

Accepted for review: 2. 7. 2021

Accepted for print: 21. 10. 2021

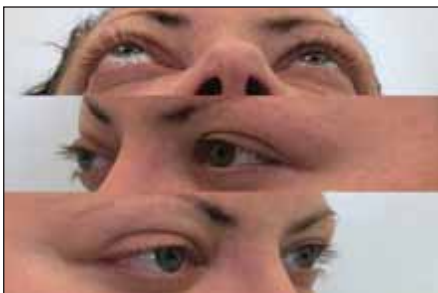

Fig. 1. Protrusion of the right bulbus.

Obr. 1. Protruze pravého bulbu.

adopted, followed by additional diagnostic tests for existing thrombophilic conditions, in that the lupus anticoagulant test was positive. The patient was indicated for life-long anticoagulant warfarin therapy.

Throughout the hospitalization period, the maximal measured protrusion of the right eye was 8 mm (Exophthalmometry: 30-105-22). Gradual regression was apparent after the administration of anticoagulant therapy. On day 6, the protrusion was diminished by 4 mm and the acute complications abating BCVA remained unchanged.

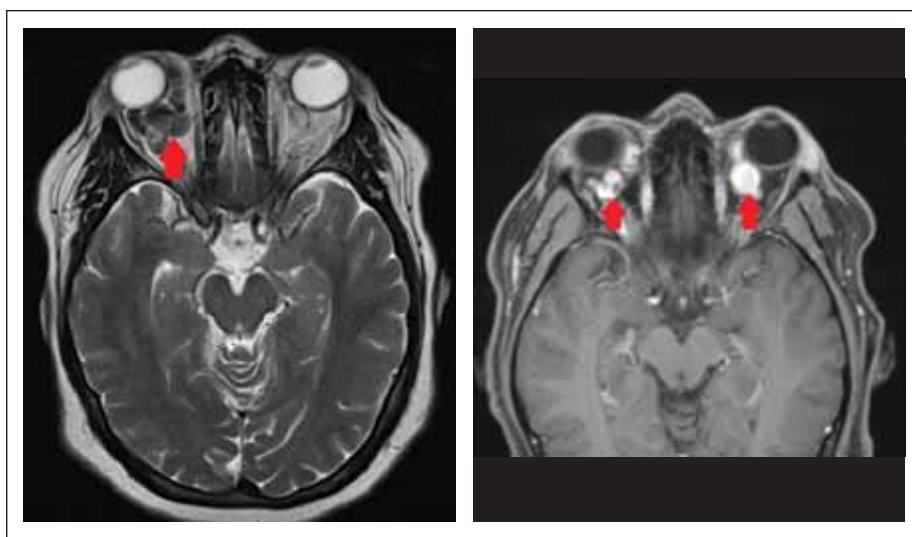


Fig. 2. (A) Transverse T2-weighted MRI scan shows thrombosis of the supraorbital vein and varices in the right orbit and presence of varices in the left orbit. (B) Transverse post-contrast T1-weighted MRI scan shows bilateral orbital varices with no signs of thrombosis 6 months after treatment.

Obr. 2. (A) Transverzální T2 vážený snímek MR ukazuje trombózu supraorbitální žíly a varixů v pravé orbitě a přítomnost varixů v levé orbitě. (B) Transverzální postkontrastní T1 vážený snímek MR ukazuje bilaterální orbitální varixy bez známek trombózy 6 měsíců po léčbě.

Follow-up examination after one month did not reveal any difference in ocular protrusion. After six months, another brain MRI was performed showing bilateral varicose vein development and dilated venous structures; however, all signs of thrombosis were now absent (Fig. 2B). Progressive atrophy of the optic nerve was observed bilaterally, but BCVA remained unchanged.

We present a rare case of SOVT with typical symptoms developed from varices of the supraorbital vein in the right orbit and a thrombophilic condition. Thanks to its early detection, the patient was successfully treated with LWMH anticoagulant therapy [6]. The varices of the orbit are mostly asymptomatic and thrombosis of the varix may be the initial manifestation of an undiagnosed asymptomatic varix [7].

Varices are typically characterized by intermittent exophthalmos, often triggered by the Valsalva manoeuvre or other similar stimuli [8,9]. Our case report describes previously unrecognized orbital varices in association with intermittent exophthalmos, which were belittled due to the psychiatric anamnesis of the patient.

The clinical symptoms of SOVT are secondary to the impaired venous drainage,

i.e., swelling of the eyelids, chemosis of the conjunctiva, dilatation of the episcleral vessels, exophthalmos with limited movability of the eye, diplopia, and decreased visual acuity [1]. Our patient manifested only some typical symptoms of impaired venous drainage. This can be explained by the early detection and therapy.

Advanced stages of the disease such as increased venous pressure in the orbit could lead to the central retinal vein occlusion or secondary glaucoma [4]. Atrophy of the optic nerve can be a late complication of untreated thrombosis [9].

Correct diagnosis of orbital varices is frequently achieved through brain MRI [9].

There is no guideline for SOVT therapy. In aseptic cases, anticoagulant LWMH therapy can be administered. Intravenous antibiotics in combination with LWMH are administered in all septic cases [1,10]. The use of corticosteroids is controversial. In aseptic aetiology, a high dose of steroids can be administered during the initial stage with subsequent shift to oral treatment. In contrast, septic SOVT with an abscess of the orbit requires surgical drainage [10].

In our patient, we opted for conservative treatment with LWMH and no antibio-

tics. The patient improved after a couple of days of treatment. Most orbital varices with no apparent thrombosis are treated conservatively, often using prismatic correction in the treatment of diplopia. Surgery is indicated only in cases of optic nerve compression and painful recurrent thrombosis [8,9]. In this case, we assume that thrombosis was the result of blood accumulation in the varix and a thrombophilic condition.

Financial Support

The work of Prof. MUDr. Pavel Kominek, Ph.D., MBA on this manuscript was supported by the Ministry of Health, Czech Republic – conceptual development of research organization (FNOs/2019).

Conflict of Interest

The authors of the manuscript certify that they have no affiliations with or involvement in any organization or entity with any financial interest, or non-financial interest in the subject matter or materials discussed in this manuscript.

References

1. Sotoudeh H, Shafaat O, Aboueldahab N et al. Superior ophthalmic vein thrombosis: What radiologist and clinician must know? *Eur J Radiol Open* 2019; 6: 258–264. doi: 10.1016/j.ejro.2019.07.002.
2. Rao R, Ali Y, Nagesh CP et al. Unilateral isolated superior ophthalmic vein thrombosis. *Indian J Ophthalmol* 2018; 66(1): 155–157. doi: 10.4103/ijo.IJO_791_17.
3. Lim LH, Scawn RL, Whipple KM et al. Spontaneous superior ophthalmic vein thrombosis: a rare entity with potentially devastating consequences. *Eye (Lond)* 2017; 28(3): 348–351. doi: 10.1038/eye.2013.273.
4. Káček M, Alexík M, Lipková B. Oklúzia hornej žily očnice – kazuistika. *Čes a slov Oftal* 2009; 65(4): 147–149.
5. Iseki S, Ito Y, Nakao Y et al. Proptosis caused by partially thrombosed orbital varix of the superior orbital vein associated with traumatic carotid-cavernous sinus fistula. *Neurol Med Chir (Tokyo)* 2010; 50(1): 33–36. doi: 10.2176/nmc.50.33.
6. Vadlamudi V, Gemmete JJ, Chaudhary N et al. Transvenous sclerotherapy of a large symptomatic orbital venous varix using a microcatheter balloon and bleomycin. *J Neurointerv Surg* 2016; 8(8): e30. doi: 10.1136/neurintsurg-2015-011777.rep.
7. Arun J, Peter AD. Simultaneous bilateral thrombosed orbital varices: a case report. *Ophthalmic Plast Reconstr Surg* 2019; 35(6): e129–e130. doi: 10.1097/IOP.0000000000001459.
8. Wade RG, Maddock TB, Anath S. Orbital varix thrombosis: a rare cause of unilateral proptosis. *BMJ Case Rep* 2013; 2013: bcr2012007935. doi: 10.1136/bcr-2012-007935.
9. Hmida B, Mnari W, Maatouk M et al. Orbital varix: rare cause of blepharospasm. *Pan Afr Med J* 2019; 32: 147. doi: 10.11604/pamj.2019.32.147.14958.
10. Kumar JB, Colón-Acevedo B, Liss J. Diagnosis and management of superior ophthalmic vein thrombosis. *Ophthalmic pearls, Oculoplastics* 2015 May. [online]. Available form URL: <https://www.aao.org/assets/17899a6f-3c6c-4562-833e-5785d027ed67/635654229297670000/may-2015-ophthalmic-pearls-pdf>.