

Spontaneous vaginal extrusion of the distal catheter of a ventriculoperitoneal shunt

Spontánní vaginální extruze distálního katetru ventrikuloperitoneálního zkratu

Dear editorial office,

A 34-year-old female had undergone a ventriculoperitoneal (VP) shunt operation due to hydrocephalus at another centre 10 years ago. The VP shunt had been revised three times and the last time it was adjusted to 100 mm H₂O at the same centre. After 7 years, the patient complained of ataxia, dizziness and vision field defects. She was brought to our hospital's emergency ward on December 28, 2016. Cranial MRI and diffusion MRI revealed bilateral cerebellar infarcts. She was drowsy and was unable to walk. The previous shunt had been placed through the right posterior parietal burr hole and it was not functional. An external ventricular drainage (EVD) was inserted through the right frontal burr hole, antiplatelet (acetylsalicylic acid 100 mg) and anticoagulant (enoxaparin sodium) medication was started. A new

shunt was placed on January 6, 2017 via the same right frontal burr hole and it was adjusted to 140 mm H₂O. The old non-functioning shunt was kept. She made a rapid neurological recovery. She was hospitalized at our clinic in January 2018 because of vaginal protrusion of the peritoneal part of the catheter. No CSF was noted at the tip of the catheter. Abdominal CT (Fig. 1) showed rupture and migration of the distal catheter. Examinations were made by the gynaecologist and general surgeon. She was scheduled for revision. The catheter spontaneously extruded as one piece during defecation. There was no sign of infection. A repeated gynaecological examination was performed and no further intervention was recommended. The extruded catheter was a part of the old shunt and for that reason, she was discharged in a good neurological and physical condition.

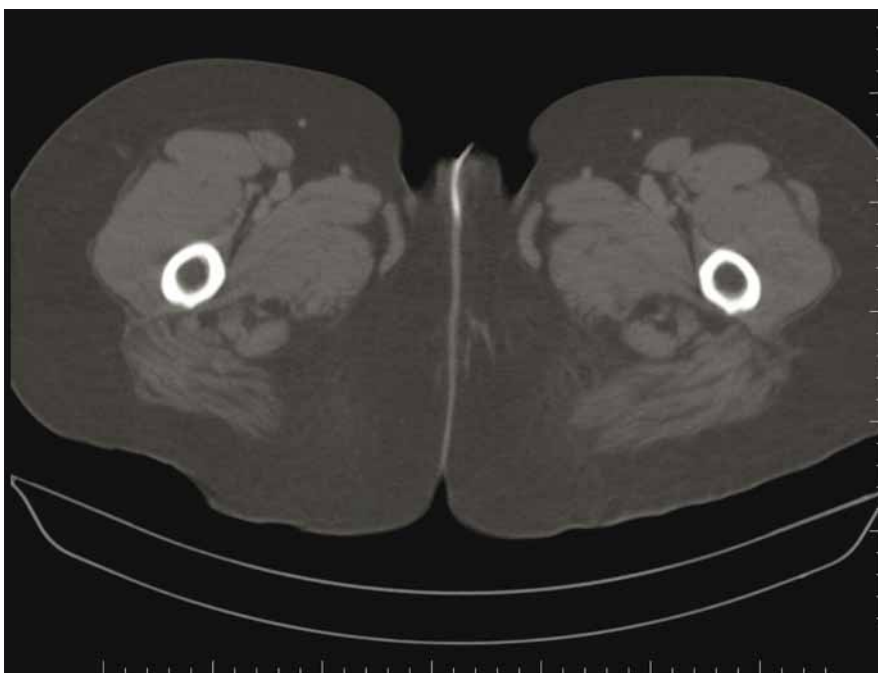


Fig. 1. Sagittal abdominal CT.

Obr. 1. Sagitální abdominální CT.

Redakční rada potvrzuje, že rukopis práce splnil ICMJE kritéria pro publikace zasílané do biomedicínských časopisů.

The Editorial Board declares that the manuscript met the ICMJE "uniform requirements" for biomedical papers.

F. Sahinturk, E. Sonmez, N. Altinors

Department of Neurosurgery, Baskent University School of Medicine, Ankara, Turkey



Fikret Şahintürk, MD

Department of Neurosurgery

School of Medicine

Baskent University

Fevzi Çakmak Caddesi 10. Sokak

No: 45 Bahçelievler

Ankara

Turkey

e-mail: fikretsahinturk@gmail.com

Accepted for review: 18. 7. 2019

Accepted for print: 29. 1. 2020

Disconnection and migration of a distal VP shunt catheter to a variety of unfavourable sites were noted in the literature. The perforation of the viscera in some instances may lead to more serious complications. Migration into the heart [1], gastric perforation and protrusion into the oral cavity [2], protrusion through the anus [3], bladder perforation [4], scrotal perforation [5] and different abdominal complications [6] are among them.

The vaginal protrusion of a distal shunt catheter is extremely rare. To date, only eight such cases have been reported in the literature (Tab. 1). Six patients were children under 2 years of age and the other two patients were adults.

Tab. 1. Clinical summary of the patients with vaginal protrusion of distal shunt catheter reported in the literature.

Author	Patient age	Medical history	Therapy
Patel 1973	11 months	meningocele repair and VA shunt, VP shunt 7 months after infection positive	total shunt removal, a new shunt inserted later
Mozingo 1974 [8]	47 years	previous tentorial meningioma surgery and VA shunt, surgery for recurrent meningioma, VP shunt, no infection	distal catheter removal, new peritoneal catheter placed
Nagulic 1996	49 days	VP shunt, no infection	removal of the abdominal part of the catheter and substitution by a new one
Farrokhi 2007	16 months	myelomeningocele repair and VP shunt at the age of 4 months, shunt infection, antibiotic therapy and EVD followed by new VP shunt	therapy for vaginal catheter protrusion is not described
Altas 2012	14 months	VP shunt when newborn, shunt revision at the age of 1 year	shunt removed, EVD for 1 week, new shunt inserted
Teegala 2012	6 months	VP shunt for Dandy-Walker malformation, infection positive	total removal of the shunt, EVD placement
Bonfield 2015 [7]	45 years	Behçet's syndrome, VP shunt for pseudo-tumor cerebri, complete shunt revision for infection, total abdominal hysterectomy for endometriosis, no infection	total removal of the shunt, a new VPL shunt inserted a week later, small opening in the vagina sutured
Lotfinia 2017	2 years	VP shunt, shunt revision, no infection	peritoneal catheter removed, replaced by a new peritoneal catheter

EVD – external ventricular drain; VA – ventriculoatrial; VP – ventriculoperitoneal

Bonfield et al [7] discussed their patient and another adult case reported by Mozingo and Cauthen [8] and found some similarities. Both patients had history of hysterectomy, extrusion was through the vaginal cuff and extrusions appeared after a relatively short time following the shunt placement. The case presented by Bonfield was diagnosed Behçet's disease. The authors claimed that prior hysterectomy and mucosal dysfunction could increase the risk in this particular patient. The exact mechanism of vaginal perforation may not be completely understood with such limited experience, but it seems that previous shunt revisions, abdominal and gynaecological intervention, an overly long distal catheter (especially in children) and infection may play a role in vaginal shunt extrusions.

Zhou et al [9] described fibrosis formation around the tube resulting in adhesion of the shunt to the nearby viscera. It is believed that fibrosis immobilizes the tube and creates risks to the abdominal organs.

Speculation that the physical characteristics of the distal shunt catheter cause perforation of the abdominal viscera has not been regarded as a probable factor.

The therapeutic approach in these cases should include defining the point of rupture of the catheter, removing it safely, repairing the opening in the vaginal wall if necessary, treatment of infection if there is any and the insertion of a new shunt in a timely manner. A temporary EVD may be inserted in shunt dependent patients until a new shunt has been placed. Only the distal catheter is removed in the absence of infection and replaced by a new one. In other instances, the whole shunt may be removed and a new one inserted. The connection of a new peritoneal catheter may be made through a small abdominal incision once the point of disconnection is clearly defined by radiology. Laparoscopic and endoscopic approaches were used and suggested for the treatment of abdominal shunt catheter complications in general.

The treatment should be multidisciplinary including the cooperation of the radiology, general surgery, gynaecology and neurosurgery departments.

References

1. Fewel ME, Garton HJ. Migration of distal ventriculoperitoneal shunt catheter into the heart. Case report and review of the literature. *J Neurosurg* 2004; 100 (2 Suppl Pediatrics): 206–211. doi: 10.3171/ped.2004.100.2.0206.
2. Yilmaz MB, Egemen E, Tonge M et al. Transoral protrusion of a peritoneal catheter due to gastric perforation 10 years after a ventriculoperitoneal shunting: case report and review of the literature. *Turk Neurosurg* 2013; 23(2): 285–288. doi: 10.5137/1019-5149.JTN.4904-11.1.
3. Adeloje A. Protrusion of ventriculo peritoneal shunt through the anus: report of two cases. *East Afr Med J* 1997; 74(5): 337–339.
4. Ueda Y, Kakino S, Hashimoto O et al. Perforation of the bladder by a peritoneal catheter: an unusual late complication of ventriculo-peritoneal shunt. *No Shinkei Geka* 1998; 26(5): 413–416.
5. Rehm A, Bannister CM, Victoratos G. Scrotal perforation by a ventriculoperitoneal shunt. *Br J Neurosurg* 1997; 11(5): 443–444. doi: 10.1080/02688699745970.
6. Odebode TO. Jejunal perforation and peroral extrusion of a peritoneal shunt catheter. *Br J Neurosurg* 2007; 21(2): 235–236. doi: 10.1080/02688690701264346.
7. Bonfield CM, Weiner GM, Bradley MS et al. Vaginal extrusion of a ventriculo-peritoneal shunt catheter in an adult. *J Neurosci Rural Pract* 2015; 6(1): 97–99. doi: 10.4103/0976-3147.143212.
8. Mozingo JR, Cauthen JC. Vaginal perforation by a Raimondi peritoneal catheter in an adult. *Surg Neurol* 1974; 2(3): 195–196.
9. Zhou F, Chen G, Zhang J. Bowel perforation secondary to ventriculoperitoneal shunt: case report and clinical analysis. *J Int Med Res* 2007; 35(6): 926–929. doi: 10.1177/147323000703500624.

Rozšířené přílohy k tomuto článku najdete na webu csnn.eu.