

# Conservative management of a ruptured Galassi III middle fossa arachnoid cyst

## Konzervativní management prasklé arachnoidální cisty Galassi III střední jámy lební

Dear editorial office, arachnoid cysts (AC) are congenital benign collections of cerebrospinal fluid (CSF) enclosed within arachnoid membranes of the meninges. These entities constitute up to 1% of intracranial lesions and their prevalence in the paediatric population is estimated at 2.6% [1]. The Sylvian fissure is the most frequent location for ACs, representing up approximately one-half of all paediatric ACs [1]. The majority of ACs are clinically silent and static in nature, whereas others undergo dynamic changes such as expansion, rupture or spontaneous disappearance. A minority of ACs are clinically symptomatic, due to increased intracranial pressure, compression of neighbouring structures or changes within the cyst such as intracystic or extracystic haemorrhage. A therapeutic algorithm for symptomatic ruptured AC is not set, however, surveys have shown preference for surgical treatment among surgeons [2]. There is a general consensus that large ACs which are clinically symptomatic should be treated surgically [3]. The following case report depicts the case of a 15-year-old boy with a Galassi Type III AC, with two episodes of transient focal neurological symptoms following cyst rupture. Later, the cyst spontaneously resolved without requiring surgical intervention.

A male patient underwent a diagnostic algorithm for epidermal nevus syndrome at the age of 6, including a brain MRI. The MRI revealed a large Galassi III AC 8.5 × 3.0 × 9.0 cm in the left frontotemporal region (Fig. 1a). It showed slight protrusion of the overlying bone with compression of the underlying brain tissue. However, due to the lack of clinical symptoms, a conservative approach consisting of regular follow-ups was agreed upon with the patient's parents. At age 15, a routine MRI showed

subtle signs of intracystic haemorrhage (Fig. 1b). Nevertheless, the patient was asymptomatic, thus, no surgical or pharmaceutical action was taken. One month later, the patient was admitted following a spontaneous episode of transient aphasia, right-sided facial nerve lesion and arm paresis. A CT was performed and showed a stable AC with signs of older bleeding, but without signs of acute haemorrhage, AC expansion or other intracranial pathologies (Fig. 1c). Even so, the patient was admitted to the paediatric ward for observation. Once admitted, one further identical episode occurred spontaneously and resolved after approximately 10 min. Fundoscopy was performed without signs of increased intracranial pressure and the patient was observed for a total of 5 days. No further episodes of transient neurological deficit occurred and the patient was discharged on the 5th day with a planned follow-up visit at the neurosurgical outpatient clinic. Six months later, a follow-up brain MRI was performed and showed almost complete resolution of the entire AC (Fig. 1d). Another MRI was performed 1 year later and showed a stable AC remnant. The patient remained symptom-free throughout the entire follow-up period.

Treatment algorithms of ACs in the paediatric population remain a controversial issue, with several treatment strategies proposed throughout literature. General management of these lesions can be divided into two categories – cases of asymptomatic and stable ACs and cases of ACs accompanied by clinical symptoms and/or dynamic changes such as cyst growth, rupture or haemorrhage.

In cases of asymptomatic ACs, there is ongoing debate whether to treat these lesions conservatively or surgically. The main

The authors declare they have no potential conflicts of interest concerning drugs, products, or services used in the study.

Autoři deklarují, že v souvislosti s předmětem studie nemají žádné komerční zájmy.

The Editorial Board declares that the manuscript met the ICMJE "uniform requirements" for biomedical papers.

Redakční rada potvrzuje, že rukopis práce splnil ICMJE kritéria pro publikace zasílané do biomedicínských časopisů.

**J. Lodin, A. Hejčl, T. Radovnický, M. Sameš**

Neurosurgical Department, J. E. Purkyne of Masaryk Hospital Krajská Zdravotní a.s., Ústí nad Labem, Czech Republic

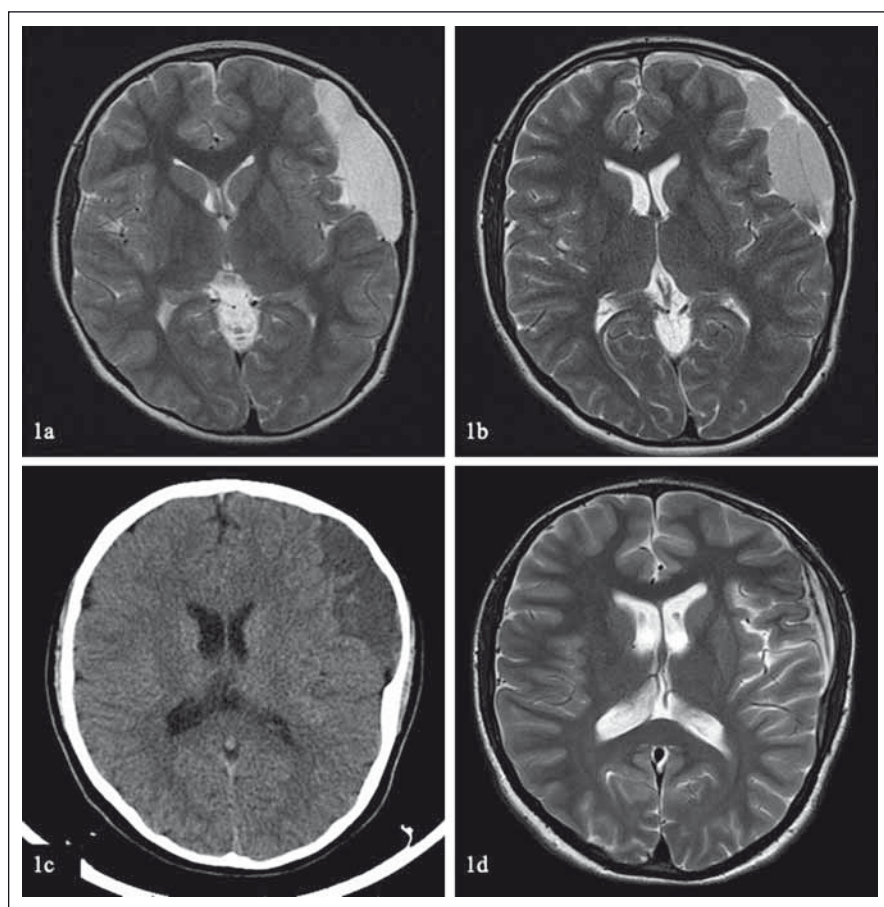


**Jan Lodin, MD**  
Department of Neurosurgery  
J. E. Purkyne University  
Masaryk Hospital  
Rabasova 13  
401 11 Ústí nad Labem  
Czech Republic  
e-mail: jan.lodin@kzcr.eu

Accepted for review: 25. 7. 2019

Accepted for print: 30. 10. 2019

argument for prophylactic surgery is fear of complications such as cyst rupture, which can lead to the formation of subdural haematomas or hygromas [2]. A recent article by Cress et al showed that the risk factors for cyst rupture or haemorrhage included cyst size of more than 5 cm and head trauma within the previous 30 days, thus supporting an active approach in these cases [4]. On the other hand, other papers state that approximately 8–27% of ACs are complicated by delayed subdural or intracerebral haematomas following minor head injury, most of which are



**Fig. 1.** (a) A Galassi III middle fossa cyst diagnosed at the age of 6. (b) Signs of older intracystic hemorrhage into the patient's arachnoid cyst on a routine MRI follow-up at age 15. (c) Patient's CT scan at admission showing a stable arachnoid cyst at the age of 15. (d) Near-total resolution of the arachnoid cyst on a 6-month follow-up MRI.

Obr. 1. (a) Cysta Galassi III střední jámy lební diagnostikována v 6 letech. (b) Známky staršího krvácení do arachnoideální cysty zobrazeném na rutinní kontrolní MR v 15 letech. (c) Pacientova vstupní CT mozku zobrazující stabilní arachnoideální cystu v 15 letech. (d) Významná regrese arachnoideální cysty zobrazené na kontrolní MR po 6 měsících.

overlooked and resolve spontaneously [5]. Furthermore, haemorrhage can result in the spontaneous resolution of ACs, due to the spilling of its contents into the subarachnoid or subdural space [6]. Consequently, the final decision on whether to treat an asymptomatic AC conservatively or surgically is based largely on surgeon and patient preference. Initially, our case presented as an asymptomatic Galassi III cyst with a diameter of more than 5 cm, with no history of head trauma. Although we believe some surgeons would choose surgical treatment based on the cyst size and Galassi III status, we opted for a conservative approach. The decision was based on the asymptomatic course of the lesion as well as a thorough consultation with the patient's parents, who preferred conservative treatment.

For cases of symptomatic ACs, there is a general consensus that surgical treatment is indicated in cases when the clinical symptoms are directly related to the cyst itself [7,8]. Data concerning treatment guidelines of ACs complicated by expansion, rupture or haemorrhage are limited to case reports [9,10]. Even so, there is a dominating tendency to treat these cases via surgical intervention, as demonstrated by recent reviews of literature [5]. However, in our opinion, it is necessary to differentiate between mild, transient clinical symptoms and severe permanent neurological deficit with intracranial hypertension, hydrocephalus or seizures. In our case, we opted for a conservative approach for the following reasons. Firstly, when the cyst rupture occurred, it was asymptomatic and randomly observed

on a follow-up MRI, with no signs of intracranial hypertension or focal neurological deficit. Secondly, the patient afterwards experienced only transient focal neurological deficit, which resolved spontaneously with no radiological signs of cyst expansion or haematoma formation. Finally, after a thorough consultation, the patient's parents preferred a conservative approach. The patient remained symptom-free throughout follow-up and a control MRI showed near-total resolution of the cyst, which we consider a satisfactory clinical and imaging result.

The therapeutic management of ACs remains a controversial topic, with most surgeons preferring surgical management of symptomatic cases. Although we believe this is the correct approach in the majority of cases, our case demonstrates that patients presenting with mild, transient or vague clinical symptoms and stable diagnostic imaging may benefit from a conservative approach. Additional studies are required to support this approach further.

## References

1. Al-Holou WN, Yew AY, Boomsaad ZE et al. Prevalence and natural history of arachnoid cysts in children. *J Neurosurg Pediatr* 2010; 5(6): 578–585. doi: 10.3171/2010.2.PEDS09464.
2. Tamburrini G, Dal Fabbro M, Di Rocco C. Sylvian fissure arachnoid cysts: a survey on their diagnostic workout and practical management. *Childs Nerv Syst* 2008; 24(5): 593–604. doi: 10.1007/s00381-008-0585-9.
3. Chen Y, Fang HJ, Li ZF et al. Treatment of middle cranial fossa arachnoid cysts: a systematic review and meta-analysis. *World Neurosurg* 2016; 92: 480–490. doi: 10.1016/j.wneu.2016.06.046.
4. Cress M, Kestle JR, Holubkov R et al. Risk factors for pediatric arachnoid cyst rupture/hemorrhage: a case-control study. *Neurosurgery* 2013; 72(5): 716–722. doi: 10.1227/NEU.0b013e318285b3a4.
5. Liu Z, Xu P, Li Q et al. Arachnoid cysts with subdural hematoma or intracystic hemorrhage in children. *Pediatr Emerg Care* 2014; 30(5): 345–351. doi: 10.1097/PEC.0000000000000128.
6. Nadi M, Nikolic A, Sabban D et al. Resolution of middle fossa arachnoid cyst after minor head trauma - stages of resolution on MRI: case report and literature review. *Pediatr Neurosurg* 2017; 52(5): 346–350. doi: 10.1159/000479325.
7. Erman T, Gocer AI, Tuna M et al. Intracranial arachnoid cysts: clinical features and management of 35 cases and review of the literature. *Neurosurgery Quarterly* 2004; 14(2): 84–89.
8. Shim KW, Lee YH, Park EK et al. Treatment option for arachnoid cysts. *Childs Nerv Syst* 2009; 25(11): 1459–1466. doi: 10.1007/s00381-009-0930-7.
9. Khilji MF, Jeswani NL, Hamid RS et al. Spontaneous arachnoid cyst rupture with subdural hygroma in a child. *Case Rep Emerg Med* 2016; 2016: 6964713. doi: 10.1155/2016/6964713.
10. Bilginer B, Onal MB, Oguz KK et al. Arachnoid cyst associated with subdural hematoma: report of three cases and review of the literature. *Childs Nerv Syst* 2009; 25(1): 119–124. doi: 10.1007/s00381-008-0728-z.