

# Tick-borne meningitis complicated by a cardioembolic intraluminal carotid artery thrombus and stroke

## Klíšťová meningitida komplikovaná kardioembolickým intraluminálním trombem v krkavici a iktem

Dear Editor,  
Intraluminal carotid thrombus (ILCT) is present in less than 2% of patients presenting with acute ischemic stroke, and 75–81% of ILCT cases are associated with atherosclerosis [1,2]. We present a rare case of acute stroke with ILCT on bare carotid artery without a plaque.

A 48-year-old man with a history of arterial hypertension presented with 6 days of fever, headache, dizziness and episodes of mild cough and throat pain. He denied smoking or any recent tick bite. On exam, patient had fever of 40 °C and pharyngeal erythema.

Initial testing revealed leukocytosis ( $11 \times 10^9/L$ ), elevated C-reactive protein (CRP) (13 mg/L). Cerebrospinal fluid analysis showed 36 mononuclears, 20 polymorphonuclears, elevated protein (0.95 g/L) and positive antibodies against European tick-borne encephalitis virus (TBEV), diagnostic of meningitis due to TBEV. A course of dexamethasone was initiated and patient's symptoms were slowly improving. On the evening of the 6<sup>th</sup> day, the patient developed sudden global aphasia and severe right-sided hemiparesis, National Institutes of Health Stroke Scale (NIHSS) was 13. He was last seen normal 3 h prior. CT

The authors declare they have no potential conflicts of interest concerning drugs, products, or services used in the study.

Autoři deklarují, že v souvislosti s předmětem studie nemají žádné komerční zájmy.

The Editorial Board declares that the manuscript met the ICMJE "uniform requirements" for biomedical papers.

Redakční rada potvrzuje, že rukopis práce splnil ICMJE kritéria pro publikace zasílané do biomedicínských časopisů.

**M. Čierny<sup>1</sup>, M. Škorňa<sup>2</sup>, S. Peška<sup>2</sup>, P. Polák<sup>3</sup>, S. Vohánka<sup>2</sup>**

<sup>1</sup> Medical College of Wisconsin  
Affiliated Hospitals, Milwaukee, WI, USA

<sup>2</sup> Neurologická klinika LF MU a FN Brno, ČR

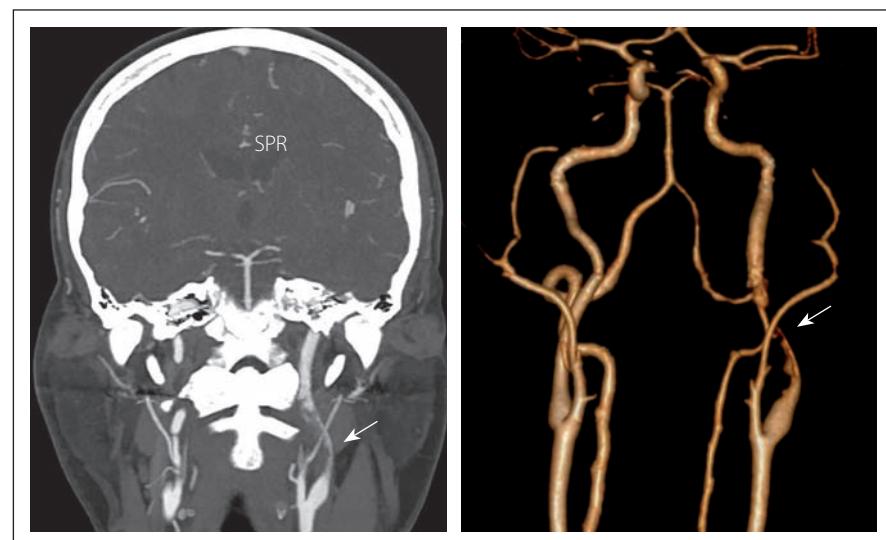
<sup>3</sup> Oddělení klinické hematologie,  
FN Brno, ČR



**MUDr. Marek Čierny**  
Medical College of Wisconsin  
9200 W Wisconsin Ave, Milwaukee  
532 26 Wisconsin  
USA  
e-mail: m.cierny@mail.muni.cz

Accepted for review: 28. 6. 2018

Accepted for print: 13. 2. 2019



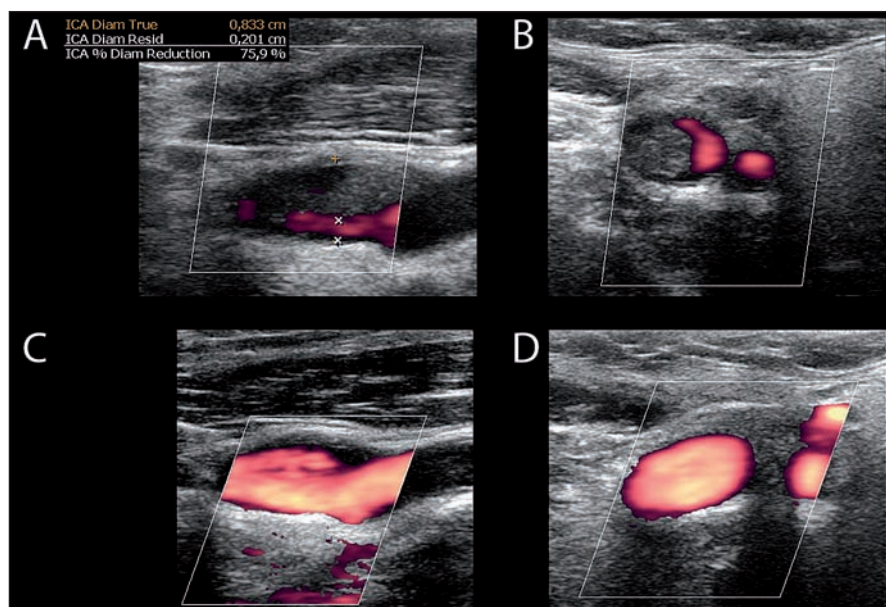
**Fig. 1.** CTA in coronal section (left) and 3D reconstruction (right) shows intraluminal filling defect in the extracranial segment (C1) of the left internal carotid artery of 3 cm in length (arrow).

Obr. 1. CTA ve frontálním řezu (vlevo) a 3D rekonstrukce (vpravo) ukazuje intraluminální defekt v extrakraniálním segmentu (C1) levé arteria carotis interna délky 3 cm (šipka).

The authors would like to thank MUDr. Jaroslav Boudný, Ph.D. (University Hospital Brno, Department of Radiology, Brno) for a valuable consultation regarding this case.

This work was supported by MH CZ – DRO (FNBr, 65269705).

was normal, without early ischemic changes. Supra-aortic CTA revealed left middle cerebral artery (MCA) thrombus, and severe stenosis of extracranial left internal carotid artery (ICA) (Fig. 1) due to an elongated filling defect, concerning for ILCT. Intravenous recombinant tissue plasminogen activator (rtPA, 70 mg) was administered. Mechanical throm-



**Fig. 2.** Carotid ultrasonography of left internal carotid artery demonstrates thrombus and 75% stenosis on longitudinal (A) and transverse (B) views. After nine days, repeated carotid ultrasonography shows complete thrombus resolution on longitudinal (C) and transverse (D) views.

Obr. 2. Karotická ultrasonografie levé arteria carotis interna prokazuje trombus a 75% stenózu v longitudinálním (A) a transverzálním (B) zobrazení. Karotická ultrasonografie opakovaná po devíti dnech ukazuje kompletní vymizení trombu v longitudinálním (C) a transverzálním (D) zobrazení.

bectomy (MT) was not performed due to perceived high risk of fragmentation and distal embolization of carotid thrombus. Within 24 h after rtPA administration, patient's deficit worsened to NIHSS 19, and a repeated head CT showed a new area of ischemia in the distribution of left M2 MCA without bleeding. Clopidogrel, low molecular weight heparin and a statin therapy was started. Carotid duplex ultrasonography (CUS) confirmed a recent thrombus in the left ICA causing a 75% stenosis, with preserved flow (Fig. 2 A, B). Further investigations revealed hypertriglyceridemia (7.8 mmol/L) and hypercholesterolemia (5.3 mmol/L). Transthoracic echocardiogram showed ejection fraction of the left ventricle of 68%, insignificant grade I mitral regurgitation and slight left atrial enlargement. A week later, the patient developed atrial fibrillation (AF) with rapid ventricular response. Nine days after the stroke, repeated CUS showed complete resolution of the thrombus with no residual stenosis (Fig. 2 C, D).

ILCT without atherosclerosis has been associated with hypercoagulable state or ma-

lignancy in 4–50% of patients [2–4], severe iron deficiency anaemia and thrombocytosis, cisplatin chemotherapy, and patent foramen ovale. Cardioembolism due to AF is associated with intracranial [4] and, in our patient, with intracarotid thrombus. Respiratory, urinary tract or CNS infection in the preceding week increases the risk of stroke by approximately 2–3 times even in young patients or those without vascular risk factors. Pre-stroke infection may be associated with large-vessel cardioembolic strokes and higher stroke severity [5,6].

The hyperacute management of acute ischemic stroke due to M2 occlusion should include rapid diagnosis, decision on rtPA administration, and MT.

The presence of a tandem (extra- and intracranial) thrombus may represent a risk for distal embolization, but guidelines (published a few years after this patient's stroke) suggest benefit of MT in this subgroup as well. It is unknown which approach to the proximal lesion (no intervention vs. angioplasty vs. stenting) is superior [7].

Recently, initial treatment with anticoagulation had been recommended for ILCT. A review of 145 cases concluded that medical treatment had lower risk and less benefits when compared to surgery, and led to thrombus dissolution in 86% of patients [2]. In one serie, 24 patients were successfully treated with initial anticoagulation: of those, 14 cases with medical therapy alone, and 10 with delayed surgery [3]. Another serie reported 20/23 cases were successfully treated with one week of initial anticoagulation, while 3/23 developed new neurologic deficit or carotid occlusion, only 2/3 patients had diffusion weighted imaging changes on MRI at one week follow-up [4]. If medical therapy does not lead to thrombus dissolution within 1–4 weeks, surgery should be considered.

In conclusion, timely CT and CTA for in-house acute ischemic stroke is crucial to guide decisions on rtPA and MT. Tandem (extra- and intracranial) occlusion is not a contraindication for MT in acute stroke with large vessel thrombosis. Patients with ILCT without atheromatous changes can be treated with acute intravenous thrombolysis, acute MT, anticoagulation, acute or delayed carotid endarterectomy or other endovascular intervention.

## References

- Iwata T, Mori T, Tajiri H et al. Safety and effectiveness of emergency carotid artery stenting for a high-grade carotid stenosis with intraluminal thrombus under proximal flow control in hyperacute and acute stroke. *J Neurointerv Surg* 2013; 5(1): 40–44. doi: 10.1136/neurintsurg-2011-010147.
- Bhatti AF, Leon LR Jr, Labropoulos N et al. Free-floating thrombus of the carotid artery: literature review and case reports. *J Vasc Surg* 2007; 45(1): 199–205. doi: 10.1016/j.jvs.2006.09.057.
- Vellimana AK, Kadkhodayan Y, Rich KM et al. Symptomatic patients with intraluminal carotid thrombus: outcome with a strategy of initial anticoagulation. *J Neurosurg* 2013; 118(1): 34–41. doi:10.3171/2012.9.JNS12406.
- Gülcü A, Gezer NS, Men S et al. Management of free-floating thrombus within the arcus aorta and supra-aortic arteries. *Clin Neurol Neurosurg* 2014; 125: 198–206. doi: 10.1016/j.clineuro.2014.08.008.
- Paganini-Hill A, Lozano E, Fischberg G et al. Infection and risk of ischemic stroke: differences among stroke subtypes. *Stroke* 2003; 34(2): 452–457. doi: 10.1161/01.STR.0000053451.28410.98.
- Grabska K, Gromadzka G, Czlonkowska A. Infections and ischemic stroke outcome. *Neurol Res Int* 2011; 2011(1): 1–8. doi: 10.1155/2011/691348.
- Powers WJ, Rabinstein AA, Ackerson T et al. 2018 Guidelines for the early management of patients with acute ischemic stroke: a guideline for healthcare professionals from the American Heart Association/American Stroke Association 2018. *Stroke* 2018; 49(3): e46–e110. doi: 10.1161/STR.0000000000000158.

Na webu csnn.eu naleznete rozšířenou verzi tohoto článku.  
Please visit csnn.eu for an extended version of this article.