

doi: 10.14735/amcsnn2017714

Baclofen and Clonazepam Overdose in a Patient with Chronic Neck and Shoulder Pain

Předávkování baklofenem a klonazepamem u pacienta s chronickou bolestí krční páteře a ramen

Dear editors,

a 42-year-old man was found at a bus stop in the evening. He had had a seizure and impaired consciousness. The emergency service administered diazepam (10 mg) and midazolam (5 mg) intravenously and supported his vital functions. He was admitted to a neurological ICU at a hospital. Upon admission, he was in a deep coma with slow photoreaction, absence of other brain reflexes and no meningeal signs. Long-lasting algetic impulses indicated symmetrical flexor responses of the limbs. Oxygen saturation was 99% with an oxygen mask; blood pressure was 148/96; heart frequency was regular and slow with 43–77/min. A CT scan of the brain and angiography of the cerebral arteries showed former hypodensity only at the right lower temporal region. This was most likely posttraumatic. An X-ray of the cervical spine was without a traumatic lesion. He received 0.5 mg of annexate and 0.5 mg of atropine intravenously without any change in his neurological status. Two hours later he received 400 mg of naloxone intravenously resulting in no change of his clinical status. Laboratory tests showed only a minor increase in liver enzymes (GMT 1.08 μ kat/l (0.25–1.42), ALT 4.42 (0.10–78), AST 2.18 (0.05–0.72), LD 4.27 (1.67–3.17)).

Serum and urine were tested for toxicology and the presence of benzodiazepines; clonazepam was at 260 ng/ml (norm: 20–70) and 7-aminoclozepam at 180 ng/ml. Serum baclofen was very high at 2700 ng/l. The patient subsequently underwent forced diuresis. The second day following admission the patient quickly regained consciousness and began to communicate during morning rounds. Nevertheless, he was still partially confused with transient motor agitation. Overall, the patient suffered from a deep coma lasting at least 12 hours.

EEG findings revealed abnormalities with slow waves appearing continuously on both sides when the delta waves rhythmic activity occurred. Sharp waves were present particularly in the frontal regions. There were no signs of status epilepticus (Fig. 1).

On the third day, the patient was transferred from the ICU to a standard department, where he complained of mild headache, drowsiness and slight dysarthria only. After 7 days of hospitalization, he was released without any medication.

A note on the history of our patient: 2 days before the onset of intoxication he was released from a prison. He traveled to the city to settle some formalities. He took baclofen and clonazepam orally for pain of the cervical spine and shoulders. He had suffered from minor bone injuries. Fifteen years ago, he had been briefly hospitalized for toxic hepatopathy. Since 2010, sporadic primary generalized epileptic paroxysms had been reported for which he first received phenytoin and later clonazepam (2 \times 2 mg).

Discussion

Baclofen is a centrally acting, lipophilic derivative of gamma-aminobutyric acid. It binds to presynaptic GABA-B receptors within the brainstem and dorsal horn of the spinal cord. It acts by restricting calcium influx into the presynaptic nerve terminal, thereby reducing release of presynaptic transmitters [1]. Baclofen is used in the treatment of muscle spasticity in patients with spinal or cerebral disorders [2]. Baclofen overdose may occur in healthy individuals who have ingested baclofen intentionally. Baclofen has also been promoted as a “fun drug” by several anecdotal experiences published on the internet [2]. Our patient took baclofen and clonazepam due to pain and muscle spasms in the

The authors declare they have no potential conflicts of interest concerning drugs, products, or services used in the study.

Autoři deklarují, že v souvislosti s předmětem studie nemají žádné komerční zájmy.

The Editorial Board declares that the manuscript met the ICMJE “uniform requirements” for biomedical papers.

Redakční rada potvrzuje, že rukopis práce splnil ICMJE kritéria pro publikace zasílané do biomedicínských časopisů.

E. Ehler¹, T. Prax¹, A. Meleková¹, I. Štětkářová²

¹ Department of Neurology, Faculty of Health Studies, Pardubice University and Pardubice Hospital, Czech Republic

² Department of Neurology, Third Faculty of Medicine, Charles University and University Hospital Královské Vinohrady, Prague, Czech Republic



Edvard Ehler, MD, PhD
Department of Neurology, Pardubice Hospital,
Kyjevská 44
532 03 Pardubice
Czech Republic
e-mail: edvard.ehler@nempk.cz

Accepted for review: 30. 8. 2017

Accepted for print: 20. 10. 2017

vertebral cervical-thoracic region but the ingested dose was not known. The drug also appeared to be used by the patient recreationally.

Adverse events of baclofen include drowsiness, headache, dizziness, and occasionally, orthostatic hypotension. Incidental or accidental overdose of this drug can cause profound central nervous system depression, including coma, hypotonia, respiratory

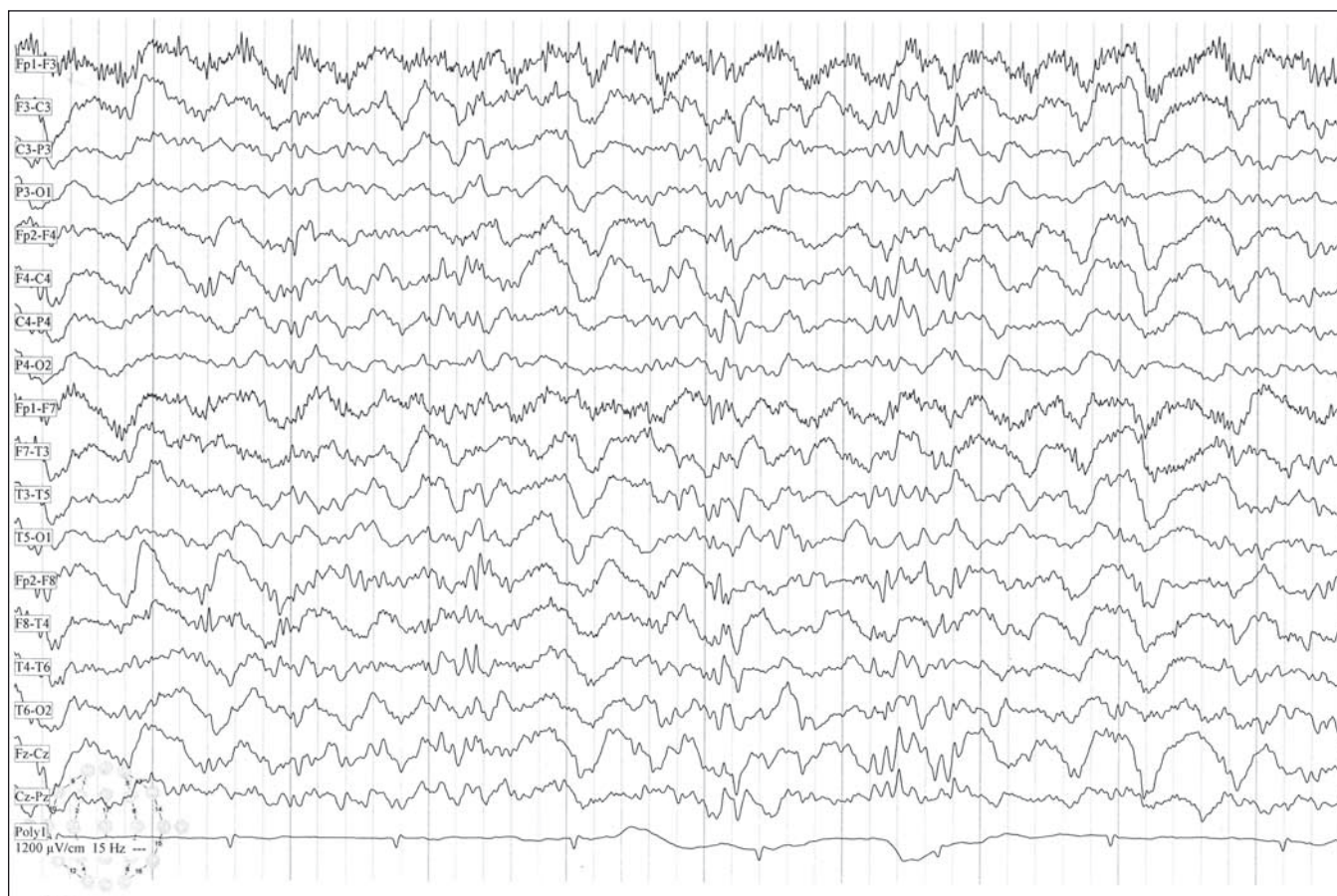


Fig. 1. Abnormal EEG with slow delta waves reflecting severe encephalopathy.

Obr. 1. Abnormální EEG s pomalými delta vlnami odpovídající těžké encefalopatii.

depression, seizures and cardiovascular effects such as bradycardia [3]. Coma with restricted brain functions frequently demands artificial ventilation. Most cases feature bradycardia (35–40 min) with only mildly reduced to normal blood pressure, without elevated intracranial pressure on the brain CT or MRI. Our patient was found at the bus stop in a coma with convulsions. At the ICU admission, his bradycardia was regular with 43 min. His blood pressure and respiratory rate were also normal. Oxygen saturation was sufficient (99% with oxygen mask) and this is why the patient was not intubated.

After oral ingestion, baclofen is rapidly absorbed from the gastrointestinal tract. Blood levels peak at 2 hours. The serum half-life is 2–6 hours but can be significantly prolonged after overdose. The majority of the drug is excreted unchanged in urine. Signs of toxicity have been reported after ingestion of as little as 100 mg of baclofen [4]. 180–800 mg [5] or 100–1500 mg [6] represents a dosage that poisons the body

when ingested. Coma in severe baclofen intoxication lasted at least 100–110 hours and most patients regained consciousness quickly [5]. They were discharged within a few days [6]. However, baclofen intoxication may also result in a very prolonged and profound coma and may in fact mimic brain death [7]. Our patient regained consciousness over the course of a few minutes after a 12-hour coma. Flumazenil was used in patients who had co-ingested benzodiazepines in order to reverse the comatose state [5]. Our patient co-ingested clonazepam and thus flumazenil and naloxone were injected but without any change in the deep coma. Baclofen blood level was extremely high at 2700 ng/ml but the patient's ventilation was sufficient and only an oxygen mask was used with good results. Recovery from coma was fast and occurred within few minutes. The duration of coma was 12 hours only and did not require artificial ventilation, though the baclofen blood level was high. We assume that long-term alcohol abuse and misuse of some drugs could explain the

patient's ability to manage this high dose of baclofen so easily. He had been released from prison 2 days prior to his hospitalization and this may explain his perfect health and fast recovery.

Severe overdose of baclofen can lead to muscle flaccidity, coma and seizures. The pro-convulsive effect of baclofen is believed to be the result of an activation of postsynaptic GABA-B receptors that have a depressant effect on inhibitory interneurons, leading to epileptogenesis [2]. An EEG can be helpful in differential diagnosis, showing typical abnormalities seen in a few other forms of intoxication only. The usual finding during intrathecal baclofen overdose is a reversible increase of slow wave activity, with periodic shape waves associated with periodic epileptic discharges [8]. Other abnormalities such as triphasic waves and burst suppressions have been described in cases of oral overdose [1,9]. Our patient was found at a bus stop in generalized convulsion and coma. The EEG was abnormal with a marked slowing, bilaterally rhythmical

delta and sparse sharp waves in the frontal regions. There were no signs of status epilepticus.

Conclusion

The present case demonstrates the importance of considering baclofen overdose in cases of severe coma in combination with generalized seizures, sinus bradycardia and normal blood pressure. Management of severe baclofen intoxication should be done at an ICU, where there is access to mechanical ventilation, forced diuresis, monitoring of vital signs with compensation of circulation, oxygen saturation and laboratory findings. Despite severe clinical manifestation of baclofen intoxication, the overall outcome is generally good.

Supported by Research Project of Charles University Progress Q35.

References

1. Sauneuf B, Totoum HK, Savary B, et al. Clinical and EEG features of acute intrathecal baclofen overdose. *Clin Neurol Neurosurg* 2012;114:84–6. doi: 10.1016/j.clineuro.2011.07.028.
2. Weisshaar GF, Hoemberg M, Bender K, et al. Baclofen intoxication: a „fun drug“ causing deep coma and non-convulsive status epilepticus – a case report and review of the literature. *Eur J Pediatr* 2012;171:1541–7. doi: 10.1007/s00431-012-1780-y.
3. Wall CC, Wasiak A, Hiclin GA. An initially unsuspected case of baclofen overdose. *Am J Crit Care*. 2006;15(6):611–3.
4. Chong CF, Wang TL. An unusual presentation of baclofen overdose. *Emerg Med J* 2005;22:673–74. doi: 10.1136/emj.2003.011908.
5. Franchitto N, Pelissier F, Lauque D, et al. Self-intoxication with baclofen in alcohol-dependent patients with co-existing psychiatric illness: an emergency department case series. *Alcohol* 2014;49(1):79–83. doi: 10.1093/alcac/agt169.
6. Anand J, Chodorowski Z, Burda P. Selected clinical aspects of acute intoxication with baclofen. *Przegl Lek* 2005;62(6):462–4.
7. Sullivan R, Hodgman MJ, Kao L, et al. Baclofen overdose mimicking brain death. *Clin Toxicol (Phila)* 2012;50(2):141–4. doi: 10.3109/15563650.2011.654209.
8. Fakhoury T, Abou-Khalil B, Blumenkopf B. EEG changes in intrathecal baclofen overdose: a case report and review of the literature. *Electroencephalogr Clin Neurophysiol* 1998;107(5):339–42.
9. Montes MI, Hernández Ortiz OH, Guerra Palacio A. Electroencephalographic burst-suppression pattern due to baclofen intoxication. *Article in Spanish Med Intensiva* 2011;35(9):584–6. doi: 10.1016/j.medin.2011.02.007.
10. Sgouros S, Charalambides C, Matsota P, et al. Malfunction of SynchroMed II baclofen pump delivers a near-lethal baclofen overdose. *Pediatr Neurosurg* 2010;46(1):62–5. doi: 10.1159/000315319.
11. Reichmuth P, Blanc AL, Tagan D. Unintentional baclofen intoxication in the management of alcohol use disorder. *BMJ Case Rep* 2015;1–3. doi:10.1136/bcr-2015-212187.

13. OLOMOUCKÉ NEUROIMUNOLOGICKÉ SYMPOZIUM S MEZINÁRODNÍ ÚČASTÍ

Umělecké centrum Univerzity Palackého v Olomouci

5.–6. října 2017

www.ms2017.upol.cz



BEHIND THE TREATMENT Biological Background of Movement Disorders Therapy

Umělecké centrum Univerzity Palackého v Olomouci

7.–8. prosince 2017

www.parkinson2017.upol.cz



Organizační zajištění:
Konferenční servis Univerzity Palackého v Olomouci,
Biskupské nám. 1, 771 11 Olomouc