

# Spinal Gossypiboma 20 years after Lumbar Discectomy – a Case Report

## Spinálny gossypibóm 20 rokov po lumbálnej diskektómii – kazuistika

### Abstract

**Introduction:** Surgical sponge retained after a surgery in the paraspinal area is a rare and mostly asymptomatic complication that, however, may represent a problem for differential diagnostics. **Case report:** Our patient was a 69-year-old man with squamous cell carcinoma of the larynx and after right-sided lumbar discectomy at the L4–L5 and L5–S1 levels performed 20 years ago. Computed positron emission tomography confirmed increased metabolism of fluorine-deoxyglucose in the sacral region. T2-weighted MRI showed a hypointense soft tissue mass with hyperintense peripheral rim. Intraoperative finding and biopsy confirmed fibrous formation with imbedded fiber gauze material. Our case is among case reports with the longest time periods between the primary spine surgery and the diagnosis of gossypiboma. **Conclusions:** Retained surgical sponges do not present with any specific clinical or radiological signs. They should be included in differential diagnosis of soft tissue masses in the paraspinal region in patients after spinal surgery. Magnetic resonance imaging and intraoperative findings are the best modality for the diagnosis of gossypibomas.

### Súhrn

**Úvod:** Pooperačne ponechaný gázový materiál v paraspinálnej oblasti predstavuje vzácnu a väčšinou asymptomatickú komplikáciu, v chronických prípadoch však môže predstavovať diferenciálno-diagnostický problém. **Kazuistika:** Pacient, 69 rokov, so spinocelulárnym karcinómom laryngu a anamnézou lumbálnej diskektómie v segmentoch L4–L5 a L5–S1 vpravo vykonanej pred 20 rokmi. Počítačová pozitronová emisná tomografia potvrdila zvýšený metabolizmus fluorodeoxyglukózy v sakrálnej oblasti. T2-vážené snímky magnetickej rezonancie zobrazili hypointenznú mäkkotkanivovú masu s hyperintenzným periférnym lemom. Peroperačný nález a biopsia potvrdili fibrotickú formáciu so zabudovanými vláknami gázového materiálu. Prezentovaná kazuistika sa zaraďuje k publikovaným prípadom s najdlhším časovým obdobím medzi spinálnym operačným výkonom a diagnózou gossypibómu. **Záver:** Ponechaný chirurgický gázový materiál nevykazuje špecifické klinické a rádiologické znaky. Mal by byť zahrnutý do diferenciálnej diagnostiky mäkkotkanivových mäs v paraspinálnej oblasti u pacientov po operácii chrbtice. Magnetická rezonancia a peroperačné nálezy predstavujú najlepšie modality pre diagnostiku gossypibómu.

The authors declare they have no potential conflicts of interest concerning drugs, products, or services used in the study.

Autoři deklarují, že v souvislosti s předmětem studie nemají žádné komerční zájmy.

The Editorial Board declares that the manuscript met the ICMJE "uniform requirements" for biomedical papers.

Redakční rada potvrzuje, že rukopis práce splnil ICMJE kritéria pro publikace zasílané do biomedicínských časopisů.

R. Opšenač, B. Kolarovszki,  
M. Benčo, R. Richterová, P. Snopko

Clinic of Neurosurgery, Jessenius  
Faculty of Medicine of Comenius  
University in Bratislava and University  
Hospital Martin



René Opšenač, MD  
Clinic of Neurosurgery  
Jessenius Faculty of Medicine  
Comenius University in Bratislava  
University Hospital Martin  
Kollárova 2  
036 59 Martin  
e-mail: opsenak@gmail.com

Accepted for review: 11. 4. 2016

Accepted for print: 17. 5. 2016

### Key words

gossypiboma – paraspinal expansion – spine – surgery – textiloma

### Kľúčové slová

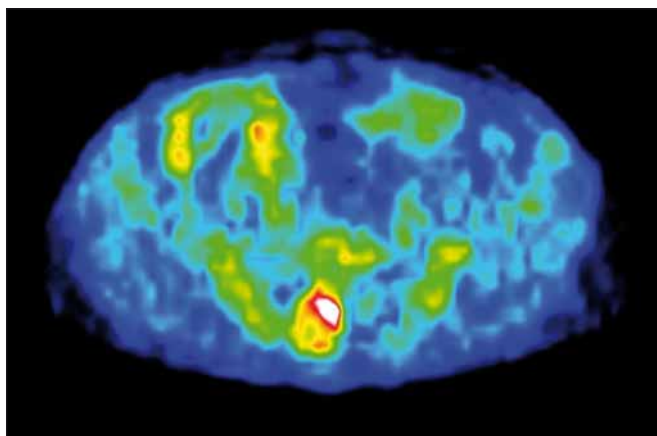
gossypibóm – paraspinálna expanzia – chrbtica – chirurgia – textilóm

### Introduction

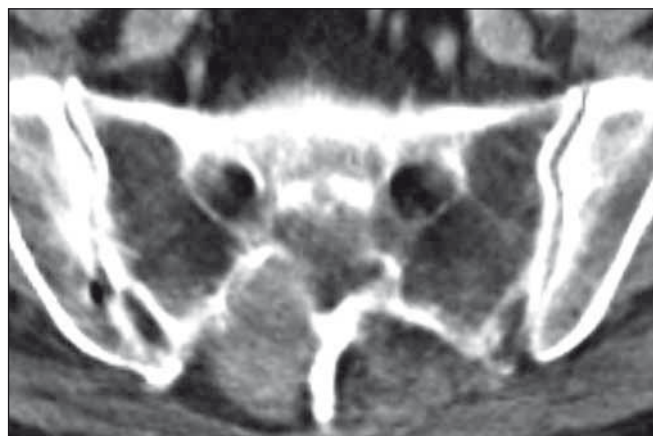
Spinal and paraspinal expansions verified by imaging methods are always a subject to differential diagnostic considerations. Rarely they

may be caused by surgical gauze material in the form of tampons or longa left in the wound after previous spinal surgery (lumbar discectomy, posterior lumbar interbody fusion, etc.).

There are two types of an organism reactions to a foreign body: *aseptic fibrous tissue reaction* that involves formation of an adhesion, encapsulation and formation of granu-



**Fig. 1. CT-PET image of the sacral segment (axial view).**  
Increased metabolism of fluorine-deoxyglucose in the sacral lesion.



**Fig. 2. Computed tomography of the sacral segment.**  
Hyperdense paraspinal expansion in the segment S1–S2 right.

loma, or *exudative type tissue reaction* – that leads to abscess [1–6]. Karcnik et al. reported a case of a foreign body reaction that had manifested at a later period after anterior cervical surgery and mimicked a solid tumor [7]. Chronic inflammatory masses could imitate tumorous lesions, paraspinal abscesses or hematomas [1,8,9]. These chronic inflammatory pseudotumors are referred to as *textilomas* (gossypibomas, gausomas, muslinomas). The term *textiloma* is used to describe a mass of a gauze material, the term *gossypiboma* describes a gauze material and surrounding reactive inflammatory granulomatous tissue [9–11]. Spinal and paraspinal *textilomas* are often asymptomatic expansions. However, sometimes they can manifest with back pain and cause spinal cord or nerve roots symptomatology based on tissue compression [1,8,12].

Various imaging methods are used to diagnose gossypiboma. If the surgical sponge has a radiopaque marker, the diagnosis can easily be made by X-ray examination [13]. Computed tomography (CT) scans of *textilomas* show well-circumscribed *hyperdense expansions* with capsular enhancement [9,14,15]. In the lumbar region, a bone erosion or a bone cavity has been reported [1,12]. These osteolytic changes with marginal sclerosis may be a sign of benign nature of the lesion and may be specific for the gossypiboma around the vertebral arch [16]. Magnetic resonance imaging (MRI) scans show *hypointensive expansions* on *T1-weighted* images and *hyperintensive expansions* on *T2-weighted* images [1,2,6,9,17]. However, in some cases, non-homogeneous intensity on *T2-weighted* images can be detected [12]. Post-contrast MRI scans show annular peri-

pheral enhancement of the expansion [1,9]. Diffusion-weighted MRI studies provide an important information to differentiate mass lesions and abscesses [18]. De Winter et al. have suggested that high fluorine-deoxyglucose (FDG) uptake in a missing foreign textile product within the surgical field may be a useful diagnostic method in the modern nuclear medicine [19].

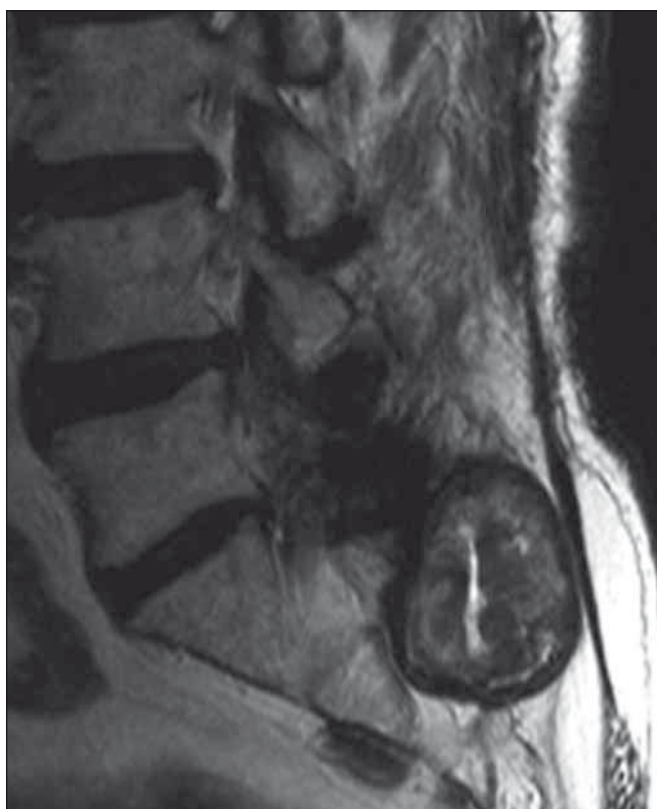
Sometimes, the left gauze material displays itself in early postoperative period as a *paraspinal abscess* with significant elevation of inflammatory parameters, or possibly as seroma with fistula formation [9,20]. This finding requires surgical revision of the wound and appropriate targeted antibiotic therapy. However, some *textilomas* remain clinically asymptomatic for many years and cause a foreign body reaction in the surrounding tissue, with development of significant *mass effect* [1–5]. The results of laboratory tests (i.e., sedimentation, C-reactive protein level and the number of the leucocytes in the blood) may depend on exudative or aseptic progression of the *textiloma* [8]. After surgical removal of a spinal or paraspinal *textiloma*, histopathological examination confirmed fibrous formation with focal monocellular and histiocytic infiltration with imbedded fiber gauze material [9].

### Case report

We present a case of a 69-year-old patient with a history of right-sided lumbar discectomy in the L4–L5 and L5–S1 segments performed in 1994. Biopsy of the right vocal cord with histopathological examination of squamous cell carcinoma was performed in September 2013. In October 2013, right-

-sided corpectomy was performed. Subsequently, CT-PET (computed positron emission tomography) showed increased metabolism of fluorine-deoxyglucose in the glottic, subglottic and sacral regions (Fig. 1). CT of the lumbosacral spine showed hyperdense paraspinal expansion on the right to the S1–S2 segment (Fig. 2). In December 2013, the patient refused laryngectomy and concomitant chemo-radiotherapy was subsequently applied. MRI of lumbosacral spine, performed in January 2014, confirmed paraspinal expansion on the right to the S1–S2 segment. The expansion was hypointense on *T1-weighted* images and it showed a hypointense core and hyperintense peripheral rim on *T2-weighted* images. The lesion also showed postcontrast peripheral enhancement (Fig. 3). Neurosurgical examination of the patient was performed in March 2014. The patient was free of symptoms related to the sacral segment, without any radicular symptomatology or sphincter disorders. Laboratory blood tests confirmed mild elevation of CRP (C-reactive protein) without leucocytosis.

Surgery was indicated based on the imaging results that suggested spinal metastasis. The surgery was performed in April 2014. The sacral canal expanded paraspinal gossypiboma with the destruction of the right-sided S1 and S2 vertebral arches was found (Fig. 4). The inflammatory pseudotumor had an ovoid shape with the size of 45 × 35 × 30 mm. Postoperative period was without any complications and the surgical wound healed. Microbiological examination of gossypiboma sample confirmed *Propionibacterium acnes*; the sample contained no mycotic infection. Post-surgical antibiotic



**Fig. 3.** MRI of the lumbosacral segment (T2-weighted sagittal image).

The soft tissue paraspinal mass with osteolysis in the level S1–S2 right.

treatment was not indicated. Histopathological examination confirmed fibro-hyalinous tissue with focal histiocytic reaction and imbedded foreign material.

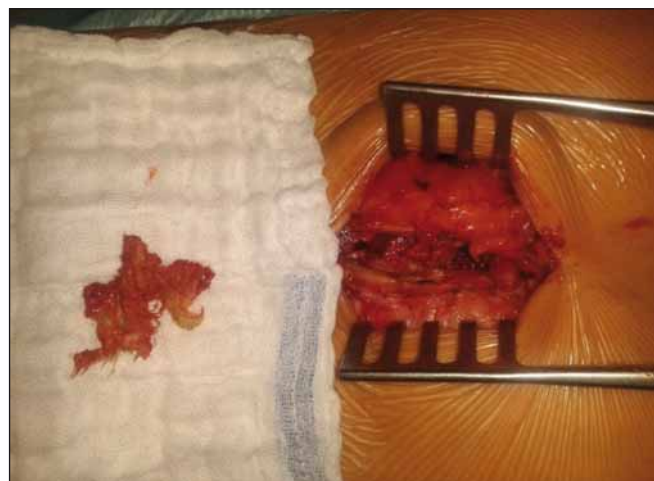### Discussion

Cotton pads, towels and sponges are used to achieve haemostasis during surgical procedures, including lumbar discectomy and other spinal surgeries. Surgical gauze material is most frequently left in the surgical wound during an emergency procedure, surgery of obese patients or when unplanned changes during the surgery occur, e.g. excessive bleeding [8,21].

In 88% of cases of a foreign body within the surgical field, an error in counting the gauze material prior to the closure of the wound occurred [18]. Although these masses and the associated complications may occur, they are rarely reported due to medico-legal consequences [7,9]. The rate of 0.7% textilomas in 10,000 lumbar disc operations has been reported [1,5,7]. At present, *gauze material with radiopaque markers* is used in clinical practice. Gossypiboma after spinal surgery has rarely been reported

Kopka et al. reported 13 cases of patients with gossypibomas in the chest and peritoneal cavity, where the gossypibomas were detected by intraoperative CT in nine cases [23]. *Intraoperative fluoroscopy* during a revision surgery can also be helpful in localizing this type of expansions. However, MRI examination is the most appropriate imaging modality to detect these lesions, there are no pathognomic radiological characteristics of these expansions.

Cotton is not the only material that can lead to problems described above. Published literature contains reports of other *haemostatic materials* (such as Gelfoam® or Surgicel®) causing the foreign body reactions undistinguishable from recurrent tumors on MRI [5,24]. Therefore, spinal textilomas can represent differential diagnostic problems, especially in conditions with a simultaneously diagnosed oncologic disease in another locality that may be associated with spinal metastatic lesions. It is necessary to consider this possibility in patients with a history of spinal surgery. The final diagnosis is only confirmed by surgery and histological examination.



**Fig. 4.** Intraoperative finding of the gossypiboma and postresectional cavity in the level S1–S2 right.

and occurs much less commonly than after an abdominal cavity surgery. Kaiser et al. reported 40 patients with retained surgical sponges in a group of 9,729 patients; two of these 40 patients underwent laminectomy [22].

In cases of chronic textilomas, microbiological examination is mostly negative [8,9,16]. In cases with infection, no microbiological agents can usually be confirmed. The role of *Staphylococcus* strains is assumed in these cases [1,17,25]. In our case report, *Propionibacterium acnes* was confirmed. This is a typical pathogen of delayed post-surgical infections. The dominant predisposing conditions for this microbiological pathogen is implantation of a foreign body [13].

Published case reports describe occurrence of paraspinal textilomas mostly after lumbar discectomy. Spinal surgery is mostly performed in distal lumbar segments [1,8,9,15–19]. In the reported cases, the diagnosis of paraspinal textilomas was made 13 days to 40 years after the primary surgical procedure [1,8,9,15,16,25]. In our case, the paraspinal textiloma was diagnosed 20 years after the primary spinal surgery. Based on the review of published cases, our case report describes one of the longest periods between the primary spinal surgery and diagnosis of gossypiboma. The longest time interval between the primary surgery and the clinical manifestation of symptoms after spinal surgery was 40 years [25]. Taylor et al. detected an intrapulmonary foreign body 43 years after thoracotomy [26]. Prevention of textilomas includes precise inspection of the wound during the surgery before closure and use of radiopaque gauze material [16].

### Conclusion

Retained surgical sponges do not show any specific clinical or radiological signs. Most

cases of textilomas are related to abdominal or thoracic surgery, only a few cases have been associated with spinal surgery. Textilomas should be included in the differential diagnosis of soft tissue masses in the paraspinal region in patients with a history of previous spinal surgery. Although chronic gossypiboma may be inert, sponges with radiopaque markers should be used to identify retained surgical sponges as soon as possible. MRI is the best radiologic modality for the diagnosis. Careful inspection of surgical field before its closure is still an important basic rule in surgery, even in the era of modern technologies and molecular and genetic medicine.

## References

- Okten AI, Adam M, Gezeran Y. Textiloma: a case of foreign body mimicking a spinal mass. *Eur Spine J* 2006; 15(Suppl 5):626–9.
- Ebner F, Tolly E, Tritthart H. Uncommon intraspinal space occupying lesion (foreign-body granuloma) in the lumbosacral region. *Neuroradiology* 1985;27(4):354–6.
- Hoyland JA, Freemont AJ, Denton J, et al. Retained surgical swab debris in post-laminectomy arachnoiditis and peridural fibrosis. *J Bone Joint Surg Br* 1988;70(4): 659–62.
- Ziyal IM, Aydin Y, Bejjani GK. Suture granuloma mimicking a lumbar disc recurrence. Case illustration. *J Neurosurg* 1997;87(3):473.
- Marquardt G, Rettig J, Lang J, et al. Retained surgical sponges, a denied neurosurgical reality? Cautionary note. *Neurosurg Rev* 2001;24(1):41–3.
- Kothbauer KF, Jallo GI, Siffert J, et al. Foreign body reaction to hemostatic materials mimicking recurrent brain tumor. Report of three cases. *J Neurosurg* 2011;95(3):503–6.
- Karcnik TJ, Nazarian LN, Rao VM, et al. Foreign body granuloma simulating solid neoplasm on MR. *Clin Imaging* 1997;21(4):269–72.
- Sahin S, Atabey C, Simsek M, et al. Spinal textiloma (gossypiboma): a report of three cases misdiagnosed as tumour. *Balkan Med J* 2013;30(4):422–8. doi: 10.5152/balkanmedj.2013.8732.
- Kucukyuruk B, Biceroglu H, Abuzayed B, et al. Paraspinal gossypiboma: a case report and review of the literature. *J Neurosci Rural Pract* 2010;1(2):102–4. doi: 10.4103/0976-3147.71725.
- Williams RG, Bragg DG, Nelson JA. Gossypiboma: the problem of the retained surgical sponge. *Radiology* 1978;129(2):323–6.
- Sheward SE, Williams AG jr, Mettler FA, et al. CT appearance of a surgically retained towel (gossypiboma) *J Comput Assist Tomogr* 1986;10(2):343–5.
- Aydogan M, Mirzanli C, Ganiyusufoglu K, et al. A 13-year-old textiloma (gossypiboma) after discectomy for lumbar disc herniation: a case report and review of the literature. *Spine J* 2007;7(5):618–21.
- Jakab E, Zbinden R, Gubler J, et al. Severe infections caused by *Propionibacterium acnes*: an underestimated pathogen in late postoperative infections. *Yale J Biol Med* 1996;69(6):447–52.
- Choi BI, Kim SH, Yu ES, et al. Retained surgical sponge: diagnosis with CT and sonography. *AJR Am J Roentgenol* 1998;150(5):1047–50.
- Dewachter P, Van De Winkel N. Retained surgical sponge. *JBR-BTR* 2011;94(3):118–9.
- Kobayashi T, Miyakoshi N, Abe E, et al. Gossypiboma 19 years after laminectomy mimicking a malignant spinal tumour: a case report. *J Med Case Rep* 2014;8:311. doi: 10.1186/1752-1947-8-311.
- Turgut M, Akyüz O, Ozsunar Y, et al. Sponge-induced granuloma ("gauzoma") as a complication of posterior lumbar surgery. *Neurol Med Chir (Tokyo)* 2005;45(4):209–11.
- Akhaddar A, Boulahrouf O, Naama O, et al. Paraspinal textiloma after posterior lumbar surgery: a wolf in sheep's clothing. *World Neurosurg* 2012;77(2):375–80. doi: 10.1016/j.wneu.2011.07.017.
- De Winter F, Huysse W, De Paepe P, et al. High F-18 FDG uptake in a paraspinal textiloma. *Clin Nucl Med* 2002;27(2):132–3.
- Marquardt G, Rettig J, Lang J, et al. Retained surgical sponges, a denied neurosurgical reality. Cautionary note? *Neurosurg Rev* 2007;24(1):41–3.
- Bani-Hani KE, Gharaibeh KA, Yaghan RJ. Retained surgical sponges (gossypiboma). *Asian J Surg* 2005;28(2):109–15.
- Kaiser CW, Friedman S, Spurling KP, et al. The retained surgical sponge. *Ann Surg* 1996;224(1):79–84.
- Kopka L, Fischer U, Gross AJ, et al. CT of retained surgical sponges (textilomas): pitfalls in detection and evaluation. *J Comput Assist Tomogr* 1996;20(6):919–23.
- Ribalta T, McCutcheon IE, Neto AG, et al. Textiloma (gossypiboma) mimicking recurrent intracranial tumor. *Arch Pathol Lab Med* 2004;128(7):749–58.
- Rajkovic Z, Altarac S, Papes D. An unusual cause of chronic lumbar back pain: retained surgical gauze discovered after 40 years. *Pain Med* 2010;11(12):1777–9. doi: 10.1111/j.1526-4637.2010.00969.x.
- Taylor FH, Zollinger RW, Edgerton TA, et al. Intrapulmonary foreign body: sponge retained for 43 years. *J Thoracic Imaging* 1994;9(1):56–9.